

Is kava really hepatotoxic?

An analysis of the known data on adverse effects of kava preparations on the liver

By Mathias Schmidt, Harsewinkel

Article extracted from <http://www.uni-muenster.de/Chemie/PB/Kava/kavaframe.html>

Abstract:

Until recently, kava has been regarded as a medicinal plant with a very favourable risk profile and a distinct efficacy. On first sight, the current discussion of potential deleterious effects of kava medication on liver metabolism seems to reverse the risk-benefit ratio, and calls for a closer look at the available data of the observed adverse effects on the liver in connection to kava intake. Within this analysis, we report background data on a total of 76 case reports dating from the years 1990 to 2002. This database consists of 37 case reports from the German “BfArM” (plus five duplicate/triplicate entries of otherwise identical case reports), five cases from the Swiss SWISSMEDIC” (formerly “IKS”), two case reports published in the German public press, three cases from the medicinal literature, 20 case reports from the US American FDA, two case reports from the British MCA, one from the Australian TGA, three from Canada, two from the French ADM and finally one case from the Pharmacovigilance Working Party of the EMEA. 14 of these cases are obviously not connected to kava intake. In 22 case reports a potentially hepatotoxic concomitant treatment was identified. In six cases there is considerable doubt concerning the causality of kava, whereas in 30 other cases the available data is too fragmentary for an assessment. This leaves four cases where a certain probability of hepatotoxic effects by kava can be established. In only one these case reports kava was taken according the dosage recommendations of the German commission E monograph. As a conclusion, hepatotoxic effects of kava intake cannot generally be ruled out. However, in comparison with alternative treatments for stress and anxiety disorders, respectively in comparison drug intake related hepatotoxicity in general, the risk of adverse liver effects seems to be very low.

Key words:

Kava, Piper methysticum, efficacy, hepatotoxicity, risk-benefit ratio, adverse effects

On November 8, 2001 the German Bundesinstitut für Arzneimittel und Medizinprodukte (BfArM, Federal Institute for Drugs and Medicinal Devices) announced a drug safety protocol concerning products containing extracts from the roots of the Oceanian kava shrub (Piper methysticum) in order to reevaluate the risk-benefit ratio in the light of recently published case reports of hepatotoxicity. This drug safety protocol was concluded on June 14, 2002 with a ban of all kava containing products, just 2 weeks after switching kava products from “OTC” to “prescription only”.

Whereas the Swissmedic, formerly called “Interkantonale Kontrollstelle” (IKS, Intercantonal control agency) had already concluded a drug safety protocol for hepatotoxic effects of kava largely without convincing results in 2000, reports from other countries are mostly scarce. Within this review, seven case rather fragmentary and therefore unassessable case reports from Australia, Canada, France and the UK are presented. In the United States, general practitioners were retrospectively asked to screen their patient data for possible cases by a “Dear doctor letter”, thus generating a total of 20 case reports from the FDA. These cases were also included into this analysis.

As a source of information for this review the following sources were used:

- line listings of the German BfArM dated September 11 resp. November 2001 and May 24, 2002
- additional details provided by the BfArM in the ban of kava products dated June 14, 2002
- additional details provided by an expert report of the BfArM in a law suit against the German authorities filed by some German producers
- additional details from the producers of the suspected kava medications
- detailed background data from the Swiss IKS forwarded to the producers of kava products in the process of the drug safety protocol of 2000
- a retrieval from the pharmacovigilance database of the WHO dated January 31, 2000
- a line listing and background information of the British MCA dated February 14, 2002
- a commented line listing of the EMEA dated July 10, 2002 including case reports from France, Canada und the UK
- a line listing of the FDA dated March 2002
- a case report published by the Australian TGA
- public media reports with additional details forwarded by the German BfArM
- the medicinal literature.

Even though the EMEA and the MCA did not use proper identifiers for the single case reports, the correlation of the data allowed a clear identification of the different case reports within the line listings, thus avoiding a multiplication of otherwise identical cases. Wherever concomitant medications were used, the medicinal literature was screened for hepatotoxicity of the respective drugs, using Medline as a database source with the search items “liver”, “hepat*”, “icter*”, “jaundice” and “transaminas*”. Wherever a more profound analysis was required, the retrieved literature was scanned for further citations of related case reports.

Table 1: The different case reports can be sorted as follows:

Classification	Case No.	Entry no.	Number of reports
Analyzed cases in total	All	–	76
Double or triple entries	97002825/97003551 01001228/01001924/01001928 01003950/01003951 99006200/01004110	2.1 2.2 2.3 2.4	–

	<p>IKS 99062501 01008989 01010222 02001135/02002378 02001776 02002090/02002836 FDA 14723 FDA 15035/15274 FDA 14538 FDA 10257 FDA 15466 MCA rep. (EMEA id. 2) Kraft et al. 2001</p>	<p>4.10 4.11 4.12 4.13 4.14 4.15 4.16 4.17 4.18 4.19 4.20 4.21 4.22</p>	
Connection to kava doubtful	<p>94006568 97002825/97003551 00008627 FDA 15281 Canadian rep. (EMEA id. 66) French rep. (EMEA id. 63)</p>	<p>5.1 5.2 5.3 5.4 5.5 5.6</p>	6
Connection to kava not assessable due to insufficient documentation	<p>92901203 99003911 99500453 01003089 99006200/01004110 01006229 01009681 01010536 02000370 02002541 02002732 01006939 02003278 02003559 02004364 02005178 02001414 Weekly magazine report FDA 11444 FDA 14951 FDA 14995 FDA 15249 FDA 15250 FDA 15252 FDA 15267 FDA 15320 Canadian rep. (EMEA id. 67) Canadian rep. (EMEA id. 65) French rep. (EMEA id. 64) Australien TGA report</p>	<p>6.1 6.2 6.3 6.4 6.5 6.6 6.7 6.8 6.9 6.10 6.11 6.12 6.13 6.14 6.15 6.16 6.17 6.18 6.19 6.20 6.21 6.22 6.23 6.24 6.25 6.26 6.27 6.28 6.29 6.30</p>	30
Possible connection to kava with mograph conform dosage	Strahl et al. 1998	7.1	1
Possible connection to kava with otherwise unknown details	Humbertson et al. 2001	7.2	1

Possible connection to kava with overdosing	IKS-2000-0014; IKS 2000-3502	8.1 8.2	2
---	---------------------------------	--	---

In total, only one case with a possible or probable connection to kava remains ([Strahl et al. 1998 \(2\)](#)), where kava was taken within the dosage recommendation of the monograph of the German commission E. In three other cases ([IKS-2000-0014](#) ; [IKS 2000-3502](#); [Humbertson et al. 2001 \(3\)](#)) the connection appears plausible. However, in two of the “possible” cases mentioned above kava was taken as a high dosage long term treatment as opposed to the intake and dosage recommendations of 120 mg of kavalactones per day as defined by the official kava monograph of the German commission E ([4](#)).

More care is required in the evaluation of case reports of adverse events

Estimates of the nature and scope of adverse drug reactions can mostly only be guessed, as in general the available data would not be sufficient for interpretation. It is especially difficult to draw quantitative conclusions from the reported data in regard to morbidity, mortality or the underlying causes of adverse drug events, and attempts to extrapolate the available data to the general population would be invalid and perhaps misleading ([5](#)).

Most of the kava case reports are fragmentary, and seemingly not much care was invested in the research of background data. The collection of facts and backgrounds of a case reports is frequently hard to achieve, as more often than not the patients and the treating physicians do not provide any substantial information. In addition, German general practitioners not used to the elucidation of adverse events often do not know how to handle case reports. When herbal medicinal products are involved, the personal likes or dislikes may also bias the evaluation. However, even the rejection of plant derived drugs must not lead to evaluations where the herbal medicinal product is automatically suspicious, and other possible causes are simply not taken into consideration. Once officially registered, a causality evaluation practically cannot be corrected. However, the official line listings are the basic material for international risk-benefit evaluations.

A typical example is the report of the occurrence of a reversible transaminitis after the intake of max. 6 capsules of a standardized kava extract in the course of one week (BfArM case no. [02002090/02002836](#)), corresponding to 50 mg of kavalactones per day ([6](#)). The establishment of the causality of kava was based on the fact that the treating physicians had read about the drug safety protocol of kava in the newspapers. The possible effects of the antirheumatic and gastric treatment of the general practitioner, consisting of sulphasalazine, diclofenac and omeprazole - all with well known liver side effects - were not taken into consideration. A closer look at the clinical data and laboratory parameters allow to assume a hepatic reaction of the idiosyncratic-metabolic type, consistent with diclofenac and omeprazole on long term treatment, but not with kava on short term and low dose intake.

When the collection of the background data finally allowed a realistic interpretation of the case report, there was already an entry into the official line listing of the BfArM based on the primary evaluation of the physicians. An international exchange of case data between the drug authorities will now show another case where kava was the suspected medication - backed by the BfArM which despite of an overwhelming mass of data simply denied the possibility of hepatic adverse events induced by the concomitant treatment. Thus, more care is required from all parties involved when it comes to speaking a verdict on a given medication.

Kava - inefficient and risky?

Drug safety protocols are a tool for the amelioration of drug safety. In the case of kava, neither a ban of kava products nor a switch from OTC to prescription only seems an adequate response to the facts derived from the case reports. However, not only the risk of kava products is discussed, but also the efficacy is questioned. So, before the potential side effects of kava and the case reports are discussed, the efficacy and quality of modern kava extracts shall be regarded.

Efficacy of kava extracts

The indication areas of extracts from kava roots are the treatment of restlessness, stress symptoms and mild anxiety disorders. As there is no addiction to kava, and side effects were not observed in a relevant magnitude, over the last decades preparations from kava were established as efficacious

and low risk alternatives to chemically defined drugs in the same field of application, especially when the use of strongly acting benzodiazepines is considered inadequate.

In the official German monograph (4) kava preparations are stated as efficacious and well tolerated medications for the treatment of nervous anxiety, inner tension and restlessness. This monograph was based on a multitude of older studies, to which meanwhile a number of confirming studies compliant to modern standards were added. In comparison to other herbal medicinal products, the claimed efficacy is rather well documented and confirmed though the positive evaluation in actual metaanalyses (7-9). The preclinical and clinical data the German monograph is leaning on was published in reviews (e.g. (10)). In table 2 some of the original studies published after the appearance of the German monograph are shown. Whereas all studies confirmed the efficacy of kava, not a single one provided hints on adverse effects - if the occasional unspecific reaction of the mild gastrointestinal type is neglected. Such reactions can be found under placebo in the same frequency. All taken together, there can be no reasonable doubt concerning the general efficacy of kava. However, the German BfArM did not accept the overwhelming mass of positive studies, arguing that not a single study was performed in a GCP compliant protocol testing the claimed indication area **and** the dosage scheme of 50-120 mg of kavalactones per day. The data from the more than 15.000 patients in open studies were equally not accepted as a proof of efficacy.

Table 2: Studies of the efficacy of kava extract preparations

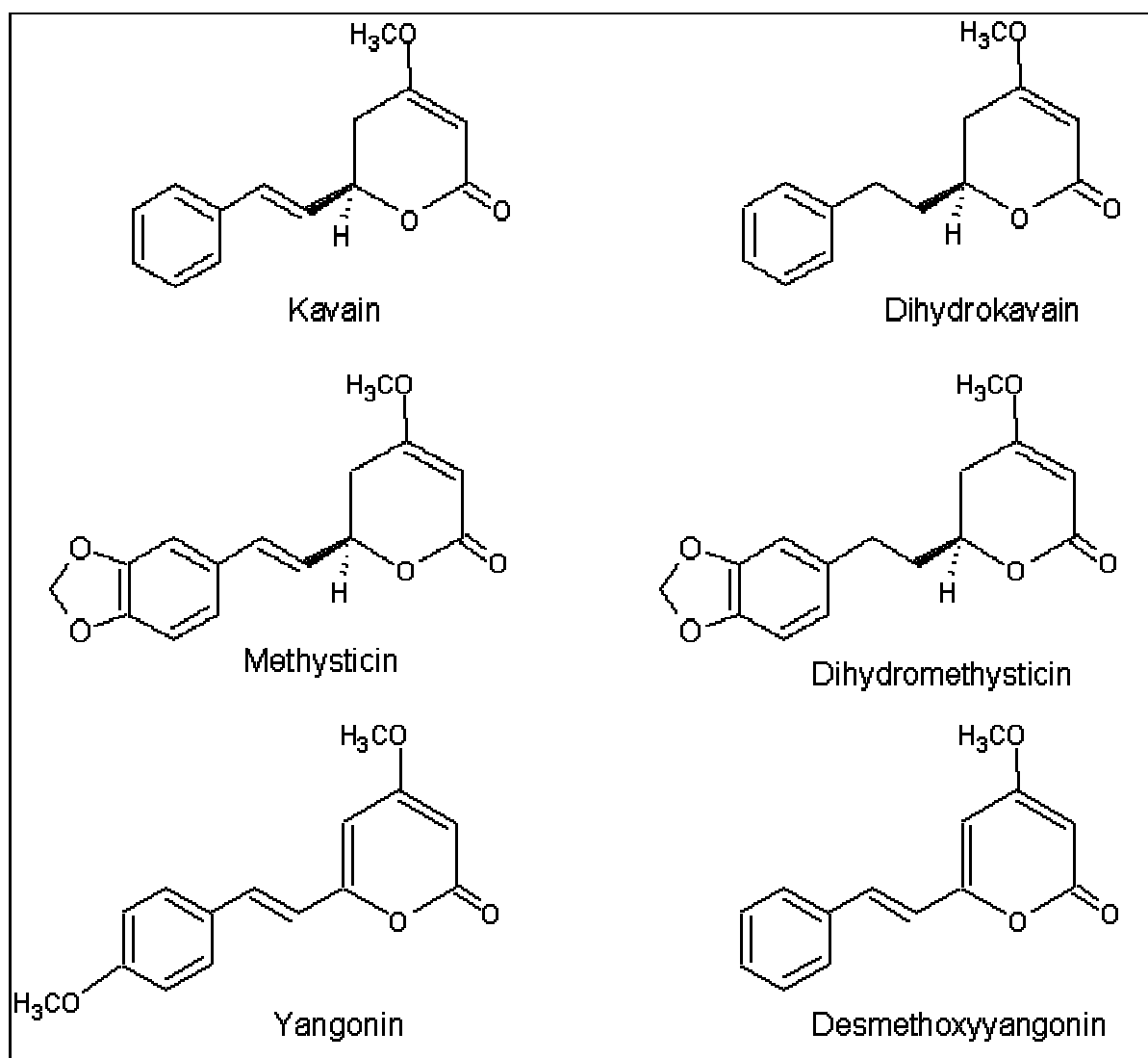
Author(s)	Study design	Diagnosis Patients (n)	Extract/ Preparation	Dosage (mg kavalactones / d)	Duration of treatment
Warnecke et al. 1989/1990	Placebo-controlled double blind study	Psychovegetative and psychoreactive disorders in peri- and postmenopause (20)	Ethanolic kava extrakt Kavosporal	2 30	12 weeks (exact data until week 8)
Kinzler et al. 1991	Placebo-controlled double blind study	States of anxiety, tensions and excitation (29)	Acetonic kava extrakt Laitan	3 70	4 weeks
Warnecke et al. 1991	Placebo-controlled double blind study	Psychovegetative and psychoreactive disorders in peri- and postmenopause (20)	Acetonic kava extrakt Laitan	3 70	8 weeks
Siegers et al. 1992	open study	States of anxiety, tension and restlessness (4049)	Acetonic kava extrakt Laitan	3 35	6 weeks
Spree und Croy 1992	open study	States of anxiety and nervous restlessness (1673)	Ethanolic kava extrakt Antares	3 40	35 days
Malsch und Kieser 1993	Placebo-controlled double blind study	Anxiety of non psychotic origin (40)	Acetonic kava extrakt Laitan	1. Week: 35-210 mg 2. – 5. Week: 210 mg	5 weeks
Woelk et al. 1993	Reference-controlled double blind study against Bromazepam / Oxazepam)	States of anxiety, tensions and excitation (55)	Acetonic kava extrakt Laitan	3 70	6 weeks
Lehmann et al. 1996	Placebo-controlled double blind study	States of anxiety, tensions and excitation (29)	Acetonic kava extrakt Laitan	3 70	28 days
Volz und Kieser 1997	Placebo-controlled double blind study	Phobia and generalised states of anxiety (52)	Acetonic kava extrakt Laitan	3 70	24 weeks
De Nicola 2002 [unpubl.]	Double blind study (200 mg kavalactones vs. 20 mg kavalactones)	Anxiety syndrom in the elderly patient (33)	Ethanolic kava extrakt corresponding to Kavasedon, Kavain Harras and Hvnoosedon	200 mg	28 days

Mittmann et al. 2000	non blinded group comparison against benzodiazepines	presurgery anxiety (26)	Ethanolic kava extrakt Kavasedon	Singe dose the evening before and the morning of the surgery, each 100 mg	acute
Boerner 2001	double blind study vs. opipramole resp. buspirone	Generalized states of anxiety (127)	Ethanolic kava extrakt Maoni	1 120	8 weeks
Co. Biocur, Holzkirchen [2001, unpubl.]	open study	States of anxiety, tensions and restlessness (ca. 3600)	Ethanolic kava extrakt Kavacur	120	
Co. redinomedica, München [2001, unpubl.]	open study	States of anxiety, tensions and restlessness (ca. 200)	Ethanolic kava extrakt Kavasedon	50 – 100	
Co. Lichtwer, Berlin [2001, unpubl.]	open study	States of anxiety, tensions and restlessness (> 1.000 patients)	Ethanolic kava extrakt Maoni	120	

Quality

The quality of herbal medicinal products is defined by botanical and agricultural parameters such as variety, origin, growth conditions and harvesting methods as well as by phytochemical parameters such as composition of active ingredients and conformity of batches.

Kava is one of the few plants, where the active constituents are well known and have been investigated in clinical and toxicological studies. The anxiolytic and spasmolytic effects are attributed to a group of styrylpyrones called kavapyrones or kavalactones. Their efficacy was demonstrated in pharmacological experiments with isolated and pure compounds. In the past, the most important active constituent was said to be Kavain, which was introduced into therapy as synthetic racemic (\pm)-Kavain. The efficacy of such products was demonstrated in clinical studies ([table 3](#)). However, the natural mixture of compounds in total extracts seems to have better effects than the isolated kavalactones, possibly due to synergistic effects or a better absorption of the compounds from the extract ([27](#)).



As the constituents responsible for the efficacy of kava are well known, the production of extracts with a reproducible composition is comparatively easy. The internal composition of roots with a defined origin is very constant and probably is genetically controlled. Thus, a constant composition of the multi-compound mixture of kavalactones is easy to maintain. In [figure 2](#), the compositions of various root lots from the same origin in Oceania is shown - without revealing relevant year-to-year differences between the single lots.

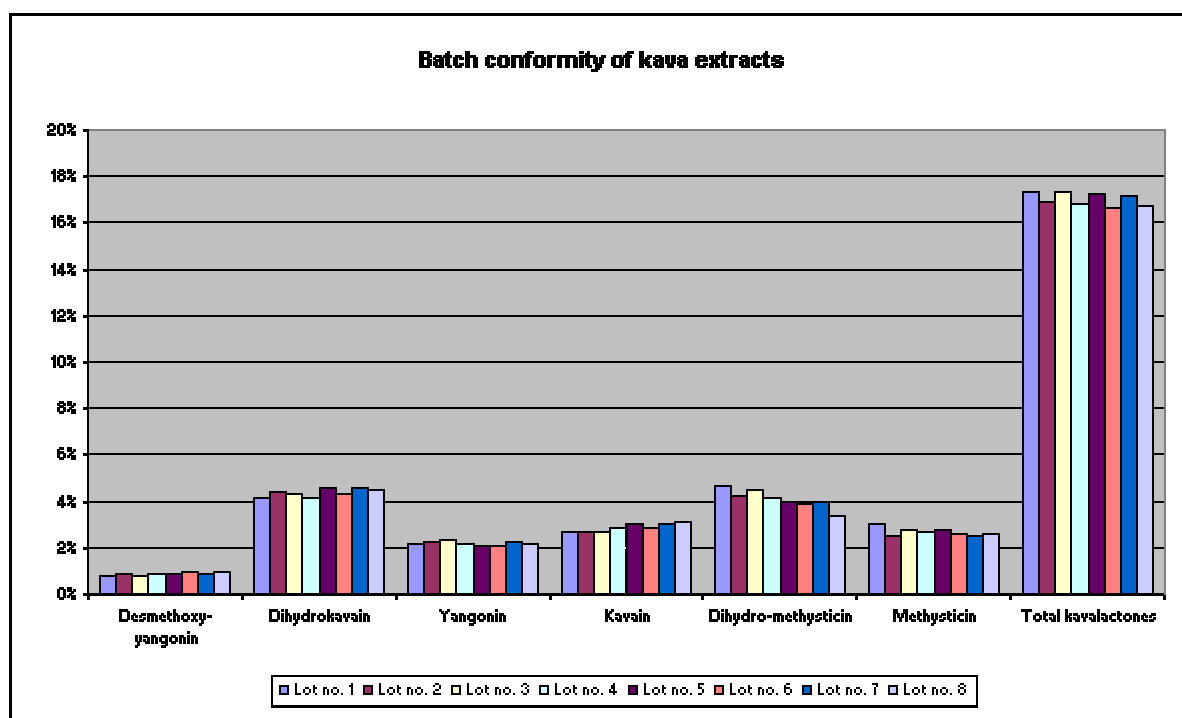


Fig. 2: Distribution of kavalactones in different lots of kava roots used for the production of Kavasedon®
 Table 3: Studies of the efficacy of (±)-Kavain

Author(s)	Study design	Diagnosis No. of Patients (n)	Extract/ Product	Dosage (mg kavalactones / d)	Duration of treatment
Möller and Heuberger 1989	Placebo controlled double blind study	Anxiety in neurotic and psychosomatic disorders (20)	Neuronika	3 200	4 weeks
Lehmann et al. 1989	Placebo controlled double blind study	Anxiety in psychosomatic and reactive disorders (26)	Neuronika	2 200	4 weeks
Unger 1998	open study	Psychovegetative disorders (2944)	Neuronika	in the first 2 weeks 2 200 mg/day, then individually dosed	4 weeks
Lindenberg and Pitule-Schödel 1990	Reference-controlled double blind study	Anxiety in neurotic and psychosomatic disorders (20)	Neuronika	3 200	28 days
Staedt et al. 1991	Placebo controlled double blind study	Anxious depression in pulmonary diseases (60)	Neuronika	3 200	12 days
Möller et al. 1992	Placebo controlled double blind study	Angst bei Benzodiazepinentzug (42)	(-)-Kavain-Capsules	3 200	6 weeks
Pilz 1994	Reference-controlled double blind study vs. thioridazine	States of anxiety (25)	(-)-Kavain-Capsules	3 200	4 weeks

Tolerability

Kava extract is doubtlessly efficacious, and the phytochemical quality is reproducible with reliability. But what about tolerability?

Kava intake does not only have a tradition of more than a thousand years in the South Pacific Area. Extracts and preparations of this plant have been used in Germany since at least 1886 (35), so one can look back on a broad experience with preparations of this plant. Up to now, all ethnopharmacological, pharmacological-toxicological and clinical data leave no room for doubts concerning the efficacy and tolerability of kava.

The implementation of the drug safety protocol was explicitly explained with the potential liver risk of kava, however in this situation a “view beyond the own fences” to evaluate other side effects and interactions should undoubtedly be made. From the patient leaflets of drugs and the section “side effects” contained therein, the actual relevance of the various possible side effects can hardly be deduced. In many cases notifications of side effects are based on reports of single cases whose causality is often not sufficiently proven. On the other hand non specific side effects like “nausea” or “dizziness” are frequently subject of spontaneous reports if the patient finds corresponding effects in the patient’s leaflet and she/he can hold the administration of a drug responsible for her/his lack of wellbeing.

Unspecific side effects

There is a range of mostly vegetative symptoms frequently reported as non desired effects of drugs which, however, are regularly observed from the administration of placebo (5;36) or even in nontreated study groups (37). Thus, symptoms like headache, nausea or dizziness are mostly subjective and occur equally in the absence of drug ingestion. Reidenberg et al. (37) reported symptomatic complaints of a type that might be considered to represent adverse drug reactions in 81% of the study population not receiving medication (37). The cause of such symptoms frequently is not the drug itself but the procedure of drug intake (38-40). Such effects are also called displacebo or nocebo effects (39). Nocebo effects frequently result from reading the product’s leaflet, others might be related to the personality structure of the patient. A special nocebo responder type has not been characterized. In the case of kava non-specific symptoms such as lack of appetite, nausea, stomach ache, diarrhea and light head ache might count among the nocebo effects. In a postmarketing surveillance study monitoring 4049 adults taking an average of 105 mg of kavalactones per day (15) 61 adverse events were reported, mainly mild and reversible gastrointestinal complaints and “allergic reactions”. In approximately half of the cases the relationship to kava was rated as probable by the treating physician. However, due to the nature of postmarketing surveillance studies these assessments can only be treated as educated guesses. Similar observations were made in another postmarketing surveillance study with 3029 participants (41). Of this study group, 69 patients reported adverse events, again mostly gastrointestinal complains, headache or dizziness, next to nine cases of “allergic reactions”. Being potentially dangerous, the latter reaction would normally imply a thorough examination. However, the notion “allergy” is mostly used in an inflationary way in Germany, mostly implying cutaneous reactions or unspecific gastrointestinal complaints in the self assessment of the patients. Even though allergies would have to be expected to occur in a given number of patients, as it would be the case with any other natural or chemically defined material, on close inspection most “allergies” stated in spontaneous reports of the patients themselves turn out to be unspecific adverse events with questionable relationship to the drug ingested. The rules of postmarketing surveillance studies do not allow to make corrections to the assessments of the treating physicians, who themselves in part just relay the indications of the patients. Thus, publications of PMS studies must always be interpreted with special care concerning indications of adverse events. Stevinson et al. (42) compared the frequency and type of adverse events in 9 placebo respectively reference controlled studies. Typical complaints were tiredness, gastrointestinal symptoms or headache. In most studies the very same adverse events occurred in higher number within the placebo or reference group, a fact that confirms the observations as unspecific “nocebo” type reactions.

Acute intoxication

Heavy chronic consumption with binge use has resulted in headache, sore eyes, generalized muscle weakness, abdominal pain, disorientation and hallucinations (43). The observation of such effects is not surprising, as kava is a rather effective muscle relaxant. Also, the sleep inducing effects in high dosages have been known since the discovery of kava by the Western seafarers (10). However, the dosage needed for triggering such effects is in no way comparable to the daily dosage of 60 to 120 mg of kavalactones as recommended by the German monograph (4), with a huge safety factor of at least 10 times the recommended dosage (42). In the case of an acute intoxication reported by Chanwai (2000), the effects disappeared by themselves few hours after the incident happened, without leaving behind any damage (43).

Allergic reactions

Allergies are stated in the package leaflets as potential adverse events of kava. We already commented on the misuse of the term as a synonym for any unspecific reaction in a timely connection to drug intake. However, allergies to kava have in fact been observed, though of cutaneous type (44). Jappe et al. described two cases with positively identified allergic skin reactions to kava intake (44). Similar reactions were observed by Guro-Razuman et al., Schmidt et al. and Süß et al. (45-47). Typically, the reactions are characterized by an

itching erythematous rash reacting positively to kava discontinuation and corticosteroids.

Oculomotoric side effects

The inclusion of oculomotoric side effects (temporal disturbances of the accommodation, enlargement of the pupils and disorders of visual coordination and eye movements) to the patient's leaflet was supposedly due to ethnopharmacological observations in the Pacific area. Comparable effects have never been published in the scientific literature on kava. In order to obtain a muscle-relaxing effect strong enough to block the eye movements unrealistically high doses would have to be taken. However, the German physician's committee for drug safety reports four unconfirmed spontaneous notifications referring to oculomotoric disorders. The risk of non-desired oculomotoric effects should be extremely low.

Extrapyramidal effects

Parkinson-like effects after ingestion of kava preparations were described in the American medicinal literature (48). They were observed in 4 patients displaying oral and lingual dyskinesias, involuntary neck extension, tonic rotations of the head, painful twisting movements of the trunc, involuntary upward deviation of the eyes and Parkinson attacks. Causality, mechanism of the observations and origin respectively quality of the used kava preparation are however unclear. Since the observed side effects were reversible by administration of biperidene, the authors deducted a dopamine-antagonistic effect of the kava extract. This side effect resembling neuroleptics is however not compatible with the pharmacological properties of the kavalactones and the kava extract. It is possible that the patients had taken neuroleptics without informing the examining personnel. Dyskinesia can have also other reasons: so far about 50 possible risk factors and underlying diseases are known. A causal relationship between extrapyramidal side effects such as dyskinesia and the ingestion of kava preparations cannot be considered as established. Moreover, it is very improbable. In a recent review of the safety of kava Stevinson et al. (2002) suggested to avoid the intake of kava for patients under treatment with levodopa (42), even though conclusive data about the effects of kava on dopamine do not exist.

Interaction: Kava and alcohol

Consumption of alcohol and intake of kava has to be seen under two aspects: under the aspect of a possible potentiation of the mutual effects and under the aspect of hepatic elimination. Like ethanol, kavalactones have CNS sedative effects, thus a mutual potentiation might be expected. Based on this assumption, the authors of the monograph "Piperis methystici rhizoma" (4) formulated: "A potentiation of the effect of CNS acting substances like alcohol, barbiturates and psycho-active drugs is possible". This interaction was underlined by animal experiments. Ethanol significantly prolongates the sleeping time after administration of kava-extract (200 mg extract per kilogram body weight p.o.) in animals. In addition, kava extract increases the toxicity of ethanol, shown experimentally by LD₅₀ measurements (49). On the other hand, in these experiments the dosage of ethanol and of kava was far from being realistic for human application. In contrast to these animal studies dosages up to 300 mg kava extract per day did not influence concentration, vigilance and motoric abilities of human test persons beyond the effects of the concomitantly given alcohol (50-53) (see table 4) - with the exception of the study of Foo and Lemon (1997) (54), who found greater impairment with the combination of kava and alcohol than with either drink alone. According to Stevinson et al. (2002) (42) these conflicting findings may be due to the quantity of kava rhizome consumed (1 g per kg bodyweight), a dose by far superior to those ingested with standardized drug preparations. In addition, the observation of aboriginal kava drinkers did not reveal impairment on cognitive performance, memory and coordination (55). In contrast, some controlled studies even led to the conclusion of enhanced cognition under the influence of kava (table 4).

Table 4: Kava studies on safety parameters and concentration ability under the influence of ethanol or psychoactive drugs

Authors	Study design	No. of patients (n)	Extract/ Product	Dosage (mg kava-lactones /	Duration of treatment
Saletu et al. 1989	Double blind study against placebo and clobazepam	Healthy volunteers (15)	Kavain Neuronika	200-600	single dose
Herberg 1991	Placebocontrolled double blind study	Healthy volunteers (20)	Acetonic kava extract Laitan	3 70	15 days
Johnson et al. 1991	Single blinded placebocontrolled study	Healthy volunteers (6)	Acetonic kava extract Laitan	300-600 mg extract	1 week
Herberg 1992	Placebocontrolled double blind study	Healthy volunteers (20)	Acetonic kava extract Laitan	3 70	8 days

Herberg 1992	Placebocontrolled double blind study	Healthy volunteers (20)	Acetonic kava extract Laitan	3 70	8 days
Münte et al. 1993	Double blind cross over study	Healthy volunteers (12)	Acetonic kava extract Laitan	600 mg extract	1 week
Gessner and Cnota 1994	Placebocontrolled double blind study in cross-over design against placebo and diazepam	Healthy volunteers (12)	Ethanolic kava extract Antares	1 120	single dose
Heinze et al. 1994	Double blind study	Healthy volunteers (12) against placebo	Acetonic kava extract Laitan	600 mg extract	1 week
Herberg 1996	Reference controlled double blind study in cross over design against bromazepam	Healthy volunteers (18)	Ethanolic kava extract Antares	2 120	14 days

Regarding the hepatic elimination in persons suffering from alcohol addiction there are no specific results of examinations for kavalactones or kava extracts, however the results of other studies with lipophilic drugs ([62-64](#)) can probably serve as a model in the case of kava. The hepatic elimination in alcohol addicts is changed as follows:

- decreased elimination of lipophilic drugs when taken with alcohol
- increased elimination due to the induction of microsomal enzymes in the alcoholic interval
- generally slowed down hepatic elimination in severe alcoholic liver damages.

In the individual patient these mechanisms can hardly be separated, and therefore the effect on the speed of elimination is not predictable ([64](#)). As a preventive measure for drug safety patients who take kava preparations should restrain from consuming alcohol.

Interaction: Kava and CNS-active drugs

There are also animal experiments treating interactions (sleep-prolongating effects) with hexobarbital ([65](#)). With barbiturates having practically disappeared from the market, the expectation of similar effects when combining kava with benzodiazepines or psycho-active drugs (e.g. [53](#)) is based on an analogy. There is one case report from Almeida et al. (1996) stating an interaction in form of disorientation and lethargy in a 54 year old man who concomitantly ingested cimetidine, alprazolam, terazosine and kava. He was hospitalized and regained his alertness after several hours ([66](#)). The patient denied the intake of an overdose of either medication or of alcohol. This report was subsequently heavily criticized. The American Botanical Council suggested that the reported state of the patient was more likely to be attributable to the intake of alprazolam alone or an interaction between alprazolam and cimetidine or terazosin.

In contrast to the case presented by Almeida et al. (1996), for a combination of kava extract in a dosage of 240 mg kavalactones per day and bromazepam in a dosage of 2x4,5 mg per day no synergistic effects could be found ([61](#)), so this matter will still have to be clarified. On the other hand, from the pharmacological point of view it does not make sense to concomitantly ingest kava and a benzodiazepine. Thus, the case presented by Almeida et al. ([66](#)) would not alter the risk-benefit ratio for the regular intake of kava preparations. As with alcohol the uncontrolled and parallel ingestion of kava preparations and psycho-active drugs should generally be avoided.

Interaction: Kava and caffeine?

Donadio et al. (2000) published a case report of a 29 year old man who - after ingesting a herbal combination product composed of 500 mg guarana, 200 mg of ginkgo and 100 mg of kava experienced a rhabdomyolysis. He stated diffuse severe muscle pain, passed a dark urine a few hours after ingesting the preparation, and displayed considerably elevated blood creatine kinase and myoglobin values without showing signs of an underlying metabolic myopathy ([67](#)). The patients condition improved within six weeks. Based on the findings of Schelosky et al. ([48](#)), who had claimed to have observed antidopaminergic effects of kava, the authors believed that the effects of the caffeine in guarana in combination with the postulated antidopaminergic and

neuromuscular blocking effects of kava might have been relevant in this adverse effect. Again, as with the mentioned case reports of extrapyramidal effects by Schelosky et al. (48), the supposed antidopaminergic effects of kava are not compatible with the known pharmacologic properties. In addition, the total amount of caffeine ingested with the herbal combination is not significantly different from what would come from normal coffee or tea consume. Even without knowing the exact amount, the caffeine content in guarana can be estimated to 8%, corresponding to 40 mg of caffeine in one tablet - approximately the amount of caffeine ingested with 1-2 cups of coffee. An average kava extract contains 4% of kavalactones, which would amount to 4 mg of kavalactones in one tablet. This dosage is surpassed by the factor of 30 in usual kava medications dosed according to the German monograph (4), and by the factor of at least 300 in the Polynesian kava drinks. One should expect that patients taking kava will not refrain from drinking coffee or tea, thus the situation of a concomitant intake of methylxanthines and kavalactones would not be the exception, but the rule for kava drinkers and patients under kava medication. If the combination really had the deleterious effects attributed to it by Donadio et al. (67), myoglobinuria would have to be counted among the most obvious and frequent adverse effects of kava.

Yellow coloring of the skin

The phenomenon of yellow coloring of skin and fingernails by ingestion of kava preparations is not - at least in Europe - a known reaction pattern. The addition to the catalogue of possible side effects can supposedly be traced back to ethnopharmacological descriptions in the Pacific area (68). There the “kava dermatopathy” after long-lasting ingestion of high kava doses is a known reaction which came to the attention of the early European seafaring explorers, and which is considered a status symbol in South Pacific upper social classes (68). The typical kava dermatopathy is however not characterized by yellow skin but by a fully reversible scaling, an effect that was used in the traditional Polynesian folk medicine in the therapy of diverse skin affections (68). As a possible mechanism of this kava-dermatopathy an accumulation of the very lipophilic kavalactones in the subcutaneous fatty tissue was discussed, the substances themselves displaying a vivid yellow color due to alternating double bonds in kavalactones of the yangonin type. Despite the possibility of confusing case descriptions of kava dermatopathy with icterus symptoms, a relationship with the hepatic function does not seem to exist. Neither skin scaling nor yellow coloring of the skin are confirmed by case reports or descriptions after ingestion of standardized kava preparations from Europe or the United States. The phenomenon should not occur with the maximum daily dose of 120 mg of kavalactones as recommended by the kava monograph of the commission E. However, there is one case report from the FDA (no. 14739) stating a thickened scaly skin after ingestion of up to 300 (!) pills per day of a kava preparation with 150 mg of extract.

Hepatic adverse effects

The case report of [Strahl et al. \(1998\)](#) was the first publication pointing to potentially serious hepatic adverse effects of kava (2). The very same patient was also examined by Russmann (2001) (69). Since then, other reports were published:

- an abstract on a case of acute hepatic failure by Humbertson et al. (2001) (3)
- a case report of cholestatic hepatitis (IKS case no. [2000-0014](#)), with Russmann et al. (2001) and Stoller (2000) giving additional details on the patient (69-71)
- a case report of liver failure with subsequent transplantation (IKS case no. [2000-3502](#)), with Russmann et al. (2001) and Escher (2001) giving additional details on the patient (70-72)
- a case report of liver failure with subsequent liver transplantation after massive overdosing of kava reported by [Kraft et al. \(2001\)](#) (1).

The available data point to an idiosyncratic-immunologic mechanism of liver toxicity, possibly combined

with a genetically determined cytochrome P450 D26 deficiency. Compared to the incident rate of drugs with known hepatotoxic potential, the overall risk of liver damage under kava appears extremely low. In addition one has to keep in mind that the documentation of the case reports listed above is far from being complete. Besides these case reports, the only hint on changes in liver function tests can be found in the report of Chanwai (2000) on the effects of kava in acute intoxication (43). Chanwai reported on a patient with regular binge use of up to 40 bowls of freshly prepared kava drink a day for 14 years. All liver function tests including bilirubin were normal, except for an isolated elevation of GGT of 94 mmol/l (normal range: 0-60) (43). Chanwai states this finding as common under kava intake, however without indicating a literature source. Possibly this statement was based on personal experience, which however is not backed by the experience with the use of kava extracts in Europa.

According to the sales figures of the German Institute of Medicinal Statistics, approximately 250 million daily doses of kava were sold during the last 10 years in German speaking countries. Correlated to this estimation, the probability of ethanolic kava extracts being responsible for hepatic adverse effects was calculated to 0.008 cases in one million of daily doses (73). Even if all 76 case reports had a certain causal connection to kava, and the daily dosages of kava in other countries than Germany were neglected, the product would still have an incidence of only 0.3 cases in one million patients. However, only four of the case reports allow to conclude a certain probability concerning the causality by kava, thus the real number would be much lower than 0.016 cases in one million daily doses - still by far a safer number than those reported for benzodiazepines. The benzodiazepines count among the most safe and tolerable medications (if the problems with addiction are neglected). Schulze et al. (74) calculated an incidence of 0.90 cases of hepatic adverse effects in one million of daily doses for bromazepam, 1.23 cases for oxazepam, and 2.12 cases for diazepam. In comparison to other drugs with a potential hepatotoxicity this incidence has to be accepted as an extremely low figure. Coming back to the case report of transaminitis mentioned above: for omeprazole, the estimations for elevated transaminase levels are calculated as 21 cases in one million of applications (75), and for diclofenac transaminitis is estimated to occur in 2.4 percent of all applications (76). In addition, severe hepatic effects occur in 36 from one million applications (77). These estimations do not seem to be a reason for safety concerns, probably as the mentioned drugs are generally handled by prescription. One should not forget that typical OTC drugs such as acetylsalicylic acid also show the same hepatic class reaction as other nonsteroidal anti-inflammatory drugs, and quite frequently lead to liver toxicity (3-5% of the patients taking acetylsalicylic acid, of those cases 3% severe and potentially life-threatening) (78-80). In addition, the switch of oral Diclofenac from prescription only to OTC is currently discussed in Germany (81).

Liver toxicity in toxicological studies

For kava extracts as well as for the isolated ingredients a number of toxicity studies were published dealing with the impact on liver parameters (39;82-88). Due to a centuries old tradition of kava ingestion in the South Pacific acute toxic effects of kava can be excluded: in the South Pacific islands, hepatic adverse reactions have never been observed (89), even though it can be expected that the folks medicine would have noted corresponding problems and passed them on in legends, taboos or ritual rules. The legends tales from Oceania concerning kava are well known from ethnologic studies and were reviewed by Lebot (10). Just one single study with Australian aborigenes and a subsequent case report of neurological manifestations on long term and highly dosed kava intoxication, combined with an increase of serum alkaline phosphatase and serum GOT levels, might be interpreted as hints on hepatic toxicity of kava (55;90). Mathews et al. (55) state a generally poor health status of the study population including malnutrition and bodyweight loss, renal and liver dysfunction, altered blood biochemistry and symptoms suggestive of pulmonary hypertension in heavy kava users. This study was heavily criticized for different reasons. The study group was selected in order to substitute heavy alcohol abuse for something more harmless. Thus, the health status of the participants was to our standards far from ideal from the beginning. In addition, the kava consume of the study group has to be considered as extreme, even by South Pacific standards, and the still ongoing consumption of alcohol was not sufficiently taken into consideration (10). Spillane et al. (91) do not give indications on alcohol consume, but clearly state an extreme consummation of kava roots.

A tendency of personal neglect on extreme and long term usage of kava was also observed in South Pacific communities (10). In the Australian study group kava will thus surely have contributed to the observed malnutrition. In the past, in the Polynesian and Melanesian regions such an abuse of kava was unthinkable due to tribal taboos and usage strictly regulated by traditions. But even if kava contributed to the poor health status of the Australian study group, the observed effects cannot be translated to the typical

Western usage in dosages far below those ingested by the Polynesian kava drinks. Anyhow, the observations of Mathews et al. in the Australian study group (55) are in no way related to the reported cases from kava drug intake, neither regarding the assumed mechanism of action nor regarding the observed adverse events. According to the manufacturers, in Europe there are meanwhile (generally unpublished) data of observational studies of at least 15.000 patients. In not one single case the liver was negatively affected.

Same background data - different evaluation

The kava case reports were evaluated by the German BfArM, the British MCA and the EMEA, using the very same background material. However, the result of this evaluation differs distinctly, as shown in table 5. In most case reports where the British respectively EMEA toxicologists had come to an “unlikely” or “not assessable” causality, the German authorities concluded a “possible” or even “probable” causality. This raises the question which scientific standards were applied in the evaluation of the case reports. Maybe it also reflects the allegations of the German experts that their expertise was not used in the process of the drug safety protocol (92).

Table 5: Evaluations of identical case data by different authorities

Review Section	BfArM case no.	BfArM	MCA	EMEA
3.1	98004297	probable	unlikely	unlikely
3.4	94901308	probable	not assessable	possible
3.5	02003010	possible		not assessable
4.2	93015209	probable	possible	possible
4.3	99006005	probable	not assessable	possible
4.7	01003950 / 01003951	certain	probable	probable / not assessable
4.15	02002090 / 02002836	probable		not assessable
4.22	Kraft et al. (2001)	probable	possible	possible
5.1	9400656	possible	possible	possible
5.3	00008627	probable	possible	possible
6.5	01004110 / 99006200	probable	possible	possible
6.6	01006229	probable	not assessable	probable
6.8	01010536	probable		not assessable
6.9	02000370	probable		not assessable
6.12	01006939	probable		not assessable
6.17	02001414	probable		not assessable

Outcome of the drug safety protocol: Immediate revocal of market authorizations

In parallel to the implementation of the drug safety protocol the German pharmaceutical companies were informed about a plan of the BfArM regarding the handling of revoked market authorizations. The announcement said that in the future appealing to a court is generally not possible when an authorization is revoked. In particular this means: If a company files a lawsuit against a revokement of a market authorization, the revokement is executed immediately, the preparation has to be taken from the market. If the company does not file a lawsuit, the revokement is executed regularly - the preparation has to be taken from the market as well. In the case of the drug safety protocol, the BfArM has made use of this new regulation, revoking all

German market authorizations without delay and with immediate execution. Kava is thus considered a highly dangerous toxin.

The revocal on June 14, 2002 was outspoken on the grounds that in addition to toxicity there is no proof of the efficacy of kava, leading to the conclusion of an imbalanced risk-benefit ratio. The existing studies were not accepted as they do not reflect the actual GCP standards, and mostly were performed with higher dosages than 120 mg kavalactones per day. The overwhelming mass of therapeutic evidence in modern studies (mostly in the correct therapeutic dosage scheme) were neglected because these studies do not meet GCP standards. In fact, the given reasons might apply to practically all drugs worldwide. Concerning the safety issue, again known facts in favor of kava were cast aside. The German authorities are decided to ignore the issue of relative safety in comparison to existing alternative therapies. In fact, the safety of the consumer concerning side effects will not be improved at all.

The regulative situation in other countries than Germany

The Swiss authorities had already concluded a drug safety protocol in 2001. As all but one case report were filed for the same product, a special extract with lipophilic organic solvents instead of ethanol/water, the Swiss authorities decided on a ban of this special extract, and on a switch from trading kava products in supermarkets to pharmacy only. The one case report with ethanolic extract was the published data of Strahl et al. (1998) (2), which identified the mechanism of action of the adverse liver event as an idiosyncratic immunologic reaction, which may in fact happen with almost any drug.

- Austria suspended all registrations following the German ban of kava in July 2002.
- In France, two non-serious liver case reports were filed, both with questionable causality for kava. The French authorities suspended all registrations for drugs containing kava extract for the duration of one year, starting on January 8, 2001. However, there was no registered kava product in France, as kava is traded as a food supplement in France, which has officially not changed. The French authorities gave a recommendation not to sell kava, but it is still legal. In view of the French colonial past in the South Pacific a complete ban if kava products might be impossible to achieve, as people in Vanuatu will not understand this course of action for a drug daily consumed in huge quantities.
- Portugal followed the French example and suspended all registrations of kava products for the duration of one year.
- In Ireland, all licensed and unlicensed kava containing products were deliberately taken off the market by the producers.
- Reportedly, the Health Sciences Authorities of Singapore have made an agreement with the producers for a deliberate withdrawal from the market.
- From Canada, three case reports were filed, two of those with highly questionable causality. The Canadian authorities issued a “stop-sale” order on August 21, 2002. However, the Canadian Health Food association called the decision “completely unacceptable”, as like in Germany Health Canada made its decision without having discussed its assessment with experts in the field of herbal medicine, and without having any new evidence on which to base their decision.
- The New Zealand Ministry of Health and the Australian Therapeutic Goods Administration published a warning regarding the consume of kava on January 16 resp. March 7, 2002. In Australia, only one very badly documented report was filed, which led to a recall of other the counter medicines in Australia on August 15, 2002.
- The department of Health of Malta also published an official warning.
- In the UK, two liver case reports were filed. In an assessment of the British MCA the authorities came to a negative risk-benefit ratio of kava, which was cited by the German BfArM in the discussion following the ban of kava in Germany. However, the British MCA did not examine the use of kava in the traditional indication area, the treatment of anxiety and stress disorders, but for gastrointestinal complaints and mild bladder discomfort, as the only three registered kava products in the UK were officially registered for these indications. Thus, no conclusions can be drawn from this assessment concerning the utility of kava in stress relief and mild anxiety disorders.
- In the US, 20 case reports were filed, however no of those showing a high probability for a causality of kava. Up to July 2002, there was no official ban or a suspension of kava registrations.

Conclusions

Experts consider kava as a medicinal plant with a very favorable risk profile and at the same time an excellent efficacy. As a reaction to the ban of kava products in Germany, the scientists in the official German expert group for phytotherapy, the so-called Commission E, publicly stated that according to their point of view the ban of kava was an overreaction and that a switch from OTC to prescription only would have been an adequate measure for risk minimization. The Commission E had assessed the risk-benefit ratio for kava as positive. Consequently, the experts regretted that their expertise was not taken into consideration by the authorities, thus questioning the sense of establishing expert commissions (93). Regarding the currently discussed hepatotoxic side effects a superficial analysis of the available data shows a distorted picture of the actual liver risk of kava extracts. After deduction of double entries and cases with no or probably no relationship to the ingestion of kava, only three relatively well documented case reports remain ([IKS-2000-](#)

[0014](#); [IKS 2000-3502](#) ; [Strahl et al. 1998 \(2\)](#)), plus the literature report of [Humbertson et al. \(2001\)](#), where the authors claim to have excluded other causative agents, however without giving any details (3). Out of these four cases only one was reported with a dosage conform to the recommendations of the kava monograph (Strahl et al. 1998 (2)). From the cases where a causal relationship seemed probable, an incidence rate of >0.02 cases per one million daily doses is calculated, corresponding to less than one case in 50 million days of application. This incidence calculation is far below the liver risk for diazepam with one case on 472.000 days of application. The ban of kava therefore increases the individual risk for the patients instead of decreasing it.

The handling of the drug safety protocol by the BfArM, using public opinion as a means to imply pressure, is as yet unprecedented. By leaking selected bits of information to the public media the BfArM succeeded in considerably upsetting consumers, pharmacists and physicians, selfcreating the necessity of acting in favor of the patients' sake. The way of spreading faulty information and of preliminarily jumping to a conclusion which should regularly stand at the outcome a real discussion process violates legal principles and at this time already is subject of legal controversies.

During the whole process of the drug safety protocol neither the producers nor the scientists and experts were really informed on the details of the case reports. It is not acceptable when information of potentially dangerous effects is denied to those who are charged with taking measures for risk minimization, but is rather given to the mass media. Companies and experts had to inform themselves on the latest developments by reading the gazettes. Obviously a detailed analysis of the backgrounds of the cases was unwanted by the authorities. If there really is a danger, this way of handling the drug safety protocol will rather endanger the consumers. If there is no danger, this way of creating facts is a scandal. The BfArM is urgently asked to treat reports of side effects with the necessary care. The producing companies are rightfully asked to put into practice the most recent pharmacovigilance guidelines. The authorities will have to be measured with the same scale.

Analysis of case reports of hepatotoxicity with kava

1. Listed case reports in total

Based on international sources and after deduction of duplicate and triplicate entries in the line listings, in August 2002 there is a total of 76 case reports of suspected hepatic side effects for kava from international sources. The number of 76 reports does however not imply 76 cases of confirmed causality. The list contains reports of highly questionable causality.

2. Duplicate entries

On close inspection, the case reports from the different sources contain a range of duplicate entries. The reporting of otherwise identical cases can lead to seemingly independent entries in the line listings, if reported from different sources such as the patient himself, the physician or the company producing the drug ([94](#);[95](#)). The redundant data entries are not only difficult to recognize, but the inflated number of cases leads to a bias in the risk evaluation for kava. Five duplicate respectively triple entries with individual identifiers can be found in the case reports.

2.1 BfArM-No. 97002825/97003551

Report of hepatic cell damage attributed to the ingestion of the products Phyto-Geriatrikum and Eunova. In spite of a deviation in the age reported for the patient (72 resp. 75 years), both cases are obviously identical: in both reports the patient's initials are „SM“, in both cases the case was filed within the same short time frame, and in both cases the same very unusual combination of medications was reported. The reported differences in the age of the patient can easily be explained by an error in the transfer of handwritten information from the adverse event registration forms.

2.2 BfArM-No. 01001228/01001924/01001928

Two of the reports refer to a 38 year old patient with the initials JR or JK, suffering from hepatitis after ingestion of Laitan in combination with penicillin V. The two cases were recognized by the BfArM as identical. By comparison of the data entries for these two cases with the third event, it becomes obvious that they are all referring to the same individual.

2.3 BfArM-No. 01003950 /01003951

Two separate reports for one patient „UW“ are recorded, wherein UW is reported to have suffered from hepatitis following oral administration of Kavain Harras N respectively Kava ratiopharm. In reality, it was a matter of one and the same patient, with a current incident from the year 2001 and a supposed earlier event in

the year 1993. However, in 1993, neither Kavain Harras N nor Kava ratiopharm were commercially available! In addition, there was no case report in 1993 stating a connection of a hepatitis with the intake of a kava product. An investigation with the physician treating the patient in 1993 showed that the patient's records did not indicate any identifiable agent responsible for the 1993 incident. The 2001 case does indeed report the ingestion of Kava ratiopharm, however there is considerable doubt concerning the causality of this medication.

2.4 BfArM-No. 99006200/01004110

The case numbers 99006200 and 01004110 refer to an incident of hepatitis on ingestion of 120 mg of an ethanolic kava extract (Antares) for the duration of more than 30 days. Both cases are very badly documented, and concern a female patient of 34 respectively 35 years. The concomitant treatment was acetaminophen respectively St. John's wort. The cases were identified as double entry by the UK Medicines Control Agency (MCA), and shall be presented as one case in the following.

3. Side effects with no relationship to the ingestion of kava

In 14 cases, the ingestion of kava preparations had nothing to do with the observation of hepatic symptoms, among them the case with fatal outcome mentioned in the early BfArM's press release, and one case reported in the line listing of the FDA.

3.1 BfArM-No. 98004297, fatal outcome)

Additional sources: MCA-listing identifier no. 9; EMEA-listing identifier no. 16.

This case report with fatal outcome widely discussed in the press refers to an 81 year old female patient (WH), who, in the course of hepatitis, suffered a fatal liver failure in May 1998. The patient had been taking Kavatio, a kava product with 60 mg of kavalactones per capsule, over 10 months in a dosage of 2 capsules per day. Due to elevated blood pressure, the patient was also prescribed hydrochlorothiazide (HCT Isis 12.5) at a dosage of 12.5 mg per day (taken for 3 months), a nitrendipin-product (Bayotensin, reportedly discontinued in January 1998) and a phyto/homeopathy combination with hawthorn extract and the homeopathic ingredients spigelia D2 and potassium carbonate D3 (Cralonin), ingested over 8 months.

The reported event included generalized icterus and a rapidly evolving acute cholestatic hepatitis. Death by liver failure occurred three days after hospitalization. The autopsy showed an acute hepatic dystrophy with histological signs of a toxic hepatopathy.

Rare cases of jaundice are known to occur from hydrochlorothiazide ([96;97](#)). For nifedipin, structurally analogous to nitrendipin, liver function impairment expressed by intrahepatic cholestasis and increased liver enzymes are labeled, backed by literature findings ([98-104](#)). However, the actual reason for the occurrence of liver symptoms in this patient is more likely to be found in long-term alcohol abuse, of which the German Federal Institute was indeed aware. One of the BfArM's listings did contain a corresponding reference, which, in contrast, was not mentioned in the press releases. However, contrasting previous indications in the BfArM's line listings, the BfArM's reasoning of the ban of kava suddenly states that there was no known alcoholic history in this case.

Moreover, just three months prior to the incident, the patient was reportedly included into the placebo group of the SCOPE study, a double blind study testing the antihypertensive drug candesartan against placebo. According to the BfArM, such an inclusion into a study group would not have taken place if any irregularities of the liver function had been noted. However, the participation in a double blind study would also not have been possible for patients taking other antihypertensive agents. In addition, SCOPE included a 1-3 month run-in period and a 2-3 year treatment. If the patient really had been included into the placebo arm of the SCOPE study as reported by the BfArM, she would not have taken the antihypertensive medication until the date of her death.

According to the histological data, the cirrhotic transformation of the liver had started long before the first administration of kava. In any case, the patient would probably have died as the result of her alcohol consumption. In addition, in the literature at least one case of alcoholic liver disease worsened by the intake of nifedipine is known ([100](#)).

The evaluation of this case by the British MCA and the EMEA as "unlikely" was based on the information on a liver failure caused by alcohol. The BfArM evaluated the case as probable due to the suddenly denied fact of alcohol by the patient.

3.2 BfArM-No. 99005139

Additional sources: MCA-listing identifier no. 24; EMEA-listing identifier no. 26.

This case, assessed by the MCA and by the EMEA as "unlikely", involves a 47 year old female patient, for

whom a transient increase in liver enzyme activity was recorded with the concomitant ingestion of high dosage fish oil and a kava product with 120 mg kavalactones per tablet (Antares). The values returned to normal without discontinuation of the kava therapy. The ingestion of highly dosed fish oil is known to produce this non-pathological reaction pattern. This possible incident is indeed rare, however it is stated in the packaging leaflets of licensed fish oil preparations. Consequently, a side effect in the liver did not take place. In contrast to previous listings, the linelisting dating from June 24, 2002, suddenly omits the comedication by fish oil and does not state the normalization of the liver values on continuation of kava.

3.3 BfArM-No. 93/0351

Additional sources: MCA-listing identifier no. 3; EMEA-listing identifier no. 3.

This case, classified as “unlikely” by the MCA and the EMEA, originates from a report of the company Schwabe in the context of a 1993 research project. The company had informed the BfArM of a 68 year old female patient, who had displayed elevated liver values prior to ingesting the kava product Laitan (70 mg of kavalactones per capsule). These values did not worsen during the course of kava therapy. Consequently, there was no side effect.

3.4 BfArM-No. 94901308

The report was filed by the treating physician.

Additional sources: SWISSMEDIC (IKS no. 94/0117); WHO case no. 94 094 296-3; MCA identifier no. 6; EMEA identifier no. 14

Patient: FE, female, 50 years

Date of entry: BfArM: May 9, 1994 / IKS: CIOMS March 16, 1994

Reported adverse effects: Hepatic cell damage, hepatitis, elevated liver enzymes, icterus

Preparation: Laitan 100 (70 mg kavalactones, acetone extract) at a dosage of 210 mg kavalactones per day, orally, for 2-3 months.

Co-medication:

- Diuretic (Hydrotrix) with 15 mg furosemide and 25 mg triamteren taken in unknown dosage and unknown duration of use.
- Atenolol of unknown dosage per tablet, 1 tablet per day, long-term ingestion (5-6 years).
- Terfenadin (Teldane) 300 mg per day, orally, long term application (12 years).

At the time of the evaluation of this case on March 16, 1994, the patient had still not fully recovered.

An alcoholic genesis of the incident was excluded. The liver biopsy pointed towards a drug induced hepatitis. The histological findings gave indications of a former hepatitis A incident. However, prior to the adverse event the liver function was inconspicuous.

It appeared as unusual that three weeks after discontinuation of the kava product a renewed increase of the transaminase values occurred, which is rather non-typical for drug-induced liver problems (105). Even though specific autoimmune antibodies could not be detected, there were signs of an autoimmune hepatitis.

Moreover, it could be shown by the histological examination of the liver tissue that the liver reactions had already begun prior to the first intake of the kava product. Prior to the incident, the patient had already completed episodes of viral infections with potential of obligatory liver participation (hepatitis A, EBV, CMV, HSV).

Assessment of the co-medication:

Furosemide and triamteren do not have any labeled adverse liver effects. In the reasoning for the ban of kava the BfArM denied the existence of adverse liver effects for furosemide. In contrast, several examples of hepatic adverse events can be found in the medicinal literature, including reproducible liver effects in animal experiments (106-112).

As individual cases of severe liver damage are labeled for atenolol, it might also be considered as a potential cause of the observed adverse event. However, as such cases seem to appear only very rarely, Atenolol probably does not provide an explanation in this case. In addition, a rechallenge with atenolol during the hospitalization of the patient was noted, without any effect on the liver function.

Due to the long term treatment over 12 years without any incident, terfenadin was not regarded as a suspected medication by the BfArM. However, a long term ingestion without any adverse effect is no guarantee that such effects will never occur, especially if the reaction is not triggered by idiosyncratic immunologic processes. As the normal dosage for terfenadine is 60-120 mg per day, the question of the influence of the 2.5 to 5fold higher dosage of 300 mg remains open. For terfenadine, increases of transaminases, cholestasis, icterus and hepatitis are labeled as potential adverse events. The liver effects of this compound are

documented ([113-115](#)).

In contrast to the evaluation provided by the BrArM, the causal relationship to kava for this case was classified as „improbable“ by the Swiss IKS in 1994. The MCA and the EMEA classified it as “possible”, at the same time referring to the potentially hepatotoxic co-medication. By the BfArM, the causality of kava was evaluated as “probable”, pointing to a positive dechallenge pattern. However, with the reoccurrence of the symptoms without any drug ingested there was no dechallenge pattern for any drug involved.

In view of the known hepatotoxic potential of the concomitant treatment, especially furosemid and terfenadine, and the possibility of an autoimmune hepatitis, the incident may be explained with other possible causes. Moreover, with the reaction already present prior to the first intake of kava, this incident was no side effect caused by kava.

3.5 BfArM-No. 02003010, liver transplant?

Additional sources: EMEA identifier no. 46

Patient: female, 47 years

Date of entry: December 30, 2001

Reported adverse effects: fatigue, nausea, discolored feces, pathologic urine, anorexia, bilirubinemia, elevated

liver enzymes, jaundice, liver failure

Preparation: Kavosporal forte (50 mg kavalactones per capsule, ethanol extract), unclear dosage

scheme (see below)

Co-medication:

- Liquid antirheumatic homeopathic preparation (Rheumeda) with bryonia D4, Ledum D4, Rhus toxicodendron D4, Ruta D4 and Spirea ulmaria D4, stabilized with methyl-4-hydroxy benzoate.
- Liver medication: Liquid mineral supplement (Gelum) with a potassium-iron-phosphate-citrate complex, stabilized with sorbic acid
- Liver medication: Amino acid complex (Polilevo), 1 tablet contains 50 mg of arginine, 25 mg of ornithine and 25 mg of citrulline
- Liver medication: silymarin (milk thistle extract)

According to the BfArM the patient was in perfect health prior to the incident.

In the course of the evolution of symptoms, the patient had complained about increasing intolerance towards certain food. Ten days before hospitalization she stated discolored feces and passed a dark urine. Initial laboratory parameters showed a bilirubinemia with 25 mg/dl, elevated transaminases with GOT 720 and GPT 620. The patient began to develop a hepatic encephalopathia. Serology for hepatitis A, B and C virus was negative, no autoimmune antibodies could be found. A liver transplant was scheduled.

The dosage of kava ingested by the patient and indicated by the different sources is highly contradictory. In a first phone call to the producer on January 21, 2002, the general practitioner indicated an intake of one capsule per day (50 mg of kavalactones) for the duration of three months. In a second phone call on January 28, 2002, the intake had risen to 17 capsules per day (850 mg of kavalactones) over an unknown period of time. In addition to the indications towards the producer, the general practitioner also filed the report to the BfArM, this time indicating an intake of 2 capsules (100 mg) per day between September 4 and December 30, 2001, however with the additional indication that the kava product was only taken twice for the duration of one week each time during the three months indicated as a time frame. Finally, the general practitioners report to the hospital mentioned 16 tablets a day, which is not only the fourth version of the dosage scheme, but also an impossibility regarding the formulation of the suspected drug as a capsule.

With the hospitalization of the patient the generation of new versions of dosage schemes did not stop: when the patient was admitted to the transplant center, the corresponding report said “up to 10 capsules per day”. In this incident, there are some more open questions. The statement of a perfect health prior to the intake of kava is questionable, as the medication taken is typical for the treatment of liver disorders. Especially silymarin, the liquid mineral complex and the amino acid complex are all officially registered as liver medications. In addition, the intake of the homeopathic mixture with the official use as an antirheumatic drug shows that either one or more underlying diseases were present and/or more hitherto unknown medications were involved.

The liver biopsy indicated extended fibrosis and liver cell necrosis, which according to the examiner’s

comment might have been due to drug induced damage. However, MR tomography yielded hints on a long existing sclerotic transformation of the liver tissue, which had started prior the the indicated time frame of kava intake.

Based on the available information the case should at best be considered as “not assessable”, as in the evaluation of the EMEA. The BfArM evaluated the case report as a “possible” causality to kava. With the results of the MR tomography indicating the start of a necrotic transformation process of the liver prior to the intake of kava, this medication cannot be held responsible for the incident.

3.6 Newspaper report (liver transplant)

This case was reported by the newspaper “Neue Westfälische” directly after the ban of kava, as a proof that the official decision was right (116). There is no corresponding case report in the line listings of the authorities, even though the regulations are to report severe adverse events without delay. As the case reportedly was observed in spring 2001, it should have appeared in the line listing dated June 24, 2002. In addition, the patient shown in a photo was the very same lady already presented as an example of a fatal outcome of a kava incident in another public media report from the weekly magazine “Stern” (117).

Patient: GH, female, 43 years
Date of entry: no entry in official line listings, media report
Reported adverse effects: liver failure with subsequent liver transplant
Preparation: note stated, “recommended dosage” for 6 weeks
Co-medication:

- St. John’s wort
- iodine compound for thyroid gland, one tablet per week
- betablocker

The patient underwent a sugery for unknown reasons in the end of 2000. As she stated, she never really recovered from this intervention, suffering from fatigue and depression. In January 2001 her physician made a urine and blood test, reportedly including the measurement of liver parameters, and handed to the patient sample packages of St. John’s wort and a kava preparation, which the patient ingested “according to the recommendation”. The thyroid gland function was also examined.

On January 12, 2001 the patient represented herself, still complaining about a general malaise. Reportedly her physician on a direct question confirmed that the liver values were normal. Even though the thyreoid gland test had not yielded a pathologic result, the physician prescribed one tablet of an otherwise not stated iodine preparation per week as a preventive measure.

Already after the first tablet, the health state worsened: the patient reported nausea, increased heart beats and an itching erythema in the breast. As a countermeasure, the physician told the patient to discontinue the iodine preparation and prescribed a betablocker instead.

Two days later, on February 22, the health state had still worsened. The patient passed a deep orange urine, the eyes were strikingly yellow. At this time according to the patient the liver values were really examined and showed pathological deviations. The physician assumed a virus hepatitis and prescribed bed-rest for the oncoming weekend.

The following Monday the patient visited another physician as she had lost confidence in her usual GP. Again, the liver function parameters were taken, and as soon as these were available the patient was transferred to one, later to another hospital. There, the physicians could not find a cause for the liver incident, but could exclude a virus hepatitis. The patient was tagged for liver transplantation, which took place on March 16 in a third hospital.

Even though in three hospitals no causal agent for the liver reaction could be identified, the intake of the kava product in January was made responsible for the adverse event by the patient. However, the unfortunate evolution of the case might have been avoided if the general practitioner had really taken the liver values in January, when the patient presented herself with - retrospectively recognizable - liver symptoms. In view of the surgical intervention stated directly before the inset of the first symptoms, and the fact that anesthesia does result in liver problems in a certain number of cases (E.g., Holt states the incidence of one case of hepatic necrosis for 35.000 patients with halothane-anesthesia (118)), the causality of kava in this case is very questionable, even more so as kava was not ingested before the first symptoms were presented to the physician. Moreover, the short application time of maximum 2 weeks until the worsening of the liver symptoms underlines the doubts concerning a participation of kava. As the patient herself stated, the treating

physician and the crews of three different hospitals were not able to find the causal agent, and the patient only retrospectively jumped to the conclusion of a causality by kava intake because at that time the media reported on the results of the Swiss drug safety protocol in June 2001.

3.7 FDA case no. 13198

Patient: female, 52 years
Date of entry: November 16, 1998

Reported adverse effects: liver cirrhosis

Preparation: Puritan's Pride (300 mg kava extract), occasionally

Co-medication:

- four dietary supplements regularly: MSM (methylsulfonylmethane), "green product", multiglandular, alfalfa
- 14 dietary supplements occasionally
- 3 OTC drugs

The patient had a history of hyperthyroidism and an exposure to hepatitis C virus. Her alcohol consume was estimated with 1-2 drinks per day and binge drinking on weekends.

With regard to the general health status, the hepatitis C infection and the binge drinking of alcohol there is a high probability that kava had no part in the evolution of this liver failure.

3.8 FDA Case no. 14810 (possible liver transplant)

Additional sources: EMEA identifier no. 52

Patient: female, 33 years

Date of entry: April 4, 2001

Reported adverse effect: nausea, diarrhea, jaundiced skin, easy bruising, possible liver transplant?

Preparation: possibly no kava was taken: follow-up with patient does not mention kava

Comedication:

- Unknown chemotherapeutic agent against lymphoma
- Ranitidine-HCl (Zantac)
- TUMS (Calcium preparation?)
- Contraceptive (LoEstrin) with 1 mg norethidrone acetate + 20 µg ethinyl estradiol
- Goldenseal (*Hydrastis canadensis*) extract
- Women's One day vitamins
- juicing

The patient was hospitalized with nausea, diarrhea, jaundiced skin and easy bruising. As a preexisting medical condition, a chemotherapy of a lymphoma one month prior to the incident was stated.

Assessment of the comedication:

From the known co-medication stated, only ranitidine is suspect in the sense that liver incidents, including severe reports, are well known ([119-138](#)), as well as for the structurally related compound cimetidine ([75;139](#)). Liver effects of the unknown chemotherapy stated can be expected.

The follow-up with the patient raised some doubts whether kava was taken in first place. With this incertitude in mind, and the existence of alternative causes the causality of kava is doubtful - if kava was taken at all, which according to the patient was not necessarily the case. The case was rated as "possible" by the EMEA.

3.9 FDA case no. 15317

Additional sources: EMEA identifier no. 56

Patient: male, 38 years

Date of entry: January 18, 2002

Reported adverse effects: liver infection, hepatitis

Preparation: not given, binge use with 8 capsules of 250 mg each once or twice per month, duration unknown.

Co-medication: St. John's wort extract

No preexisting medical condition was stated.

The assessment of the British MCA indicated a negative testing of hepatitis virus A-C, as well as a weekly alcohol consume of 3-4 glasses of wine. However, the case was filed as a liver infection. As liver infections would have to be caused by microbiological agents such as hepatitis virus, a connection to kava does

obviously not exist, in spite of the binge use. The case was evaluated as “probable” by the EMEA.

3.10 FDA case no. 15319

Additional sources: EMEA identifier no. 57
Patient: male, 63 years
Date of entry: January 2, 2001
Reported adverse effects: hepatitis C, hepatocellular liver injury, nausea, hematemesis
Preparation: kava formula (Kawaform?) with 300 mg kava extract plus magnesium orotate and additional herbs, once daily for 6 weeks
Co-medication:

- Enalapril maleate 20 mg + hydrochlorothiazide 12,5 mg per day, started 5 months prior to kava intake

As a preexisting medical condition hypertension was stated.

Assessment of the comedication:

Rare cases of jaundice are known to occur from hydrochlorothiazide ([96;97](#)).

The potential hepatotoxicity of ACE inhibitors is well known. Thus, for enalapril corresponding case reports can be found in the literature ([140-150](#)) as well as for the structurally related compounds captopril ([141](#)) and lisinopril ([151-153](#)).

However, the case was filed as a hepatitis C infection. The causal agent of the incident thus was neither enalapril nor kava but a viral infection. The causality of kava was rated as “unlikely” by the EMEA.

3.11 FDA case no. 15465/15476

Patient: male, 48 years
Date of entry: February 3, 2002
Reported adverse effects: “liver pain”
Preparation: not given, 1-2 units per day from December 10 to December 15, 2001.
Co-medication: none stated

As a preexisting medical condition liver dysfunction was stated.

As liver disorders cannot be felt by pains in the liver itself, the indication of liver pain is highly questionable, even more so as from the duration of kava intake one would not expect toxic effects of idiosyncratic origin.

There is a high probability that this report had no connection to kava.

3.12 FDA case no. 15556

Patient: male, 72 years
Date of entry: February 25, 2002
Reported adverse effects: hepatitis C related liver problems
Preparation: Kava capsules (Hi-Health), two capsules per day for two weeks
Co-medication: valerian

As a preexisting medical condition liver damage by hepatitis C was stated. The case was filed as a self report because the patient believed that kava had aggravated the existing liver problems. It may be speculated in how far the media coverage of the drug safety protocol has instilled a certain nocebo effect in predisposed patients. With objective data missing in this case, the individual feelings of a patient cannot be used as a measure for the dangers of a given medication. Fact is that the liver symptoms were not caused by kava but preexisted as a hepatitis C infection, which classifies this incident as a case without connection to kava intake.

3.13 MCA case report (EMEA identifier no. 1)

Patient: male, 40 years
Reported adverse effects: sore throat, nose bleeds, abnormal LFTs
Preparation: not stated, dosage unknown
Co-medication: none stated

The patient reportedly recovered after stopping kava.

As a preexisting condition heavy alcohol intake was noted with approximately six bottles of wine a week.

The causality of kava was evaluated as “possible” by the EMEA, possibly based on the supposed dechallenge pattern. However, no further details are known, and with the heavy alcohol abuse the incident might well be explained with the known alternative cause, especially if the symptoms sore throat and nose bleeds are taken into consideration.

3.14 EMEA case report identifier no. 38

The EMEA reportedly obtained the case report from the German BfArM.

Patient: female, 54 years
Reported adverse effects: gall bladder pain
Preparation: not stated, 120 mg/day over an unknown period of time
Co-medication:

- Triamteren
- Thyroxin
- Benalapril

The outcome of the case is unknown. There is no further information, e.g. on preexisting medical conditions or examinations confirming an adverse effect on the liver.

Gall bladder pain may have causes completely independent from liver metabolism, e.g. cholelithiasis. Thus, it is doubtful if there was an adverse event on the liver in first place. The causality was evaluated as “unassessable” by the EMEA. As case like this should not be discussed as a possible proof of hepatotoxicity of kava. In the German drug safety protocol, this adverse event was not included in the line listings of the BfArM on which the ban was finally based.

4. Causal relationship with concomitant medication probable

In the causality evaluation of suspected cases of adverse drug effects, possible influences from the co-medication must be taken into consideration. In 22 case reports the circumstances and the ingestion of other medications with known liver damaging potential leave considerable doubt concerning the causality of kava.

In principle, the participation of kava cannot be absolutely ruled out, even if the co-medication provides solid evidence for other causes. Hence, the following case reports are classified as „unlikely“.

As the official BfArM line listings display some obviously erroneous information with regard to the way of application (the correct way being confirmed either by other sources and/or by the nature of the concomitant treatment, like dermatic preparations which cannot be given systemically), the following data may in some cases divert from the official line listings.

4.1 BfArM-No. 90003882

Additional sources: MCA-identifier no. 1, EMEA-identifier no. 10

Patient: HM, female, 69 years

Date of entry: October 10, 1990

Reported adverse effects: Jaundice, cholestatic hepatitis

Preparation: Neuronika (200 mg D,L-Kavain), 2x daily, orally over an unknown period of time

Co-medication:

- Acetylsalicylic acid (ASS ratiopharm), 1x daily, orally, in unknown dosage.
- Diuretic (Dehydro Sanol) with 5-10 mg bemetizid and 10-20 mg triamteren, 1x daily, orally, in unknown dosage.
- 400 or 600 mg pentoxifyllin (Rentylin), 2x daily, orally, in unknown dosage.

The patient fully recovered.

Assessment of the co-medication:

For acetylsalicylic acid, impaired liver function in individual cases is labeled. In addition, drug is known to produce icteric increases of transaminases rather frequently (3-5% of the patients taking acetylsalicylic acid, of those cases 3% severe and potentially life-threatening) ([78-80](#)), the adverse reaction even being considered a class reaction for NSAID (see section [9.4](#)).

For the diuretic drug combination, icterus, liver function impairment, elevated blood lipid levels and jaundice are labeled as possible adverse events.

For pentoxifyllin, intrahepatic increases of transaminases and alkaline phosphatase is labeled and confirmed in rare literature reports ([154](#)).

Due to the known hepatotoxic effects of the co-medication it can be assumed that kava had no part in the genesis of this case. Due to the potentially hepatotoxic concomitant treatment the report was classified as “unassessable” by the MCA and the EMEA.

4.2 BfArM-No. 93015209

The report was filed by the treating physician.

Additional sources: SWISSMEDIC (IKS no. 93/0274); WHO case no. 93 166 384-3;
MCA identifier no. 4; EMEA identifier no. 12

Patient: SB, female, 39 years

Date of entry: December 3, 1993

Start of symptoms: June 19, 1993

Reported adverse effects: Painful abdomen, nausea, vomiting, jaundice.

Preparation: Laitan 100 (70 mg kavalactones, acetone extract), at a dosage of 210 mg kavalactones per day, orally, for 3 months

Co-medication:

- Diazepam, orally, at a dosage of 10 mg when needed for six months.
- Contraceptive (Gravistat): ethinylestradiol 0.05 mg + levonorgestrel 0.125 mg, 1x daily, orally, for 16 years.
- L-Thyroxin 75 µg / day, systemic, for 3 months.

The patient was hospitalized with nausea, gastrointestinal complaints, inappetence and icterus. The symptoms had started 12 weeks after the intake of the kava product. An ethanolic origin of the liver function impairment could be excluded. After discontinuation of kava the liver function returned to normal.

Assessment of the co-medication:

L-Thyroxin does not seem to have a hepatotoxic potential.

For contraceptive estrogen/progesterone combinations, cases of cholelithiasis, anicteric hepatitis and cholestatic icterus are labeled. For a more detailed analysis, see section [9.2](#). The BfArM excluded the causality for the contraceptive agent by referring to the long term application: within the 16 years of ingestion, never any liver anomaly occurred. Even though the proven tolerability in this specific patient cannot be taken as a proof that an adverse event with this drug would never occur.

For diazepam, very rare cases of jaundice and temporary increases of transaminases are labeled. For a more detailed analysis of the medicinal literature on the hepatotoxic potential of benzodiazepines, see section [9.1](#).

In the final evaluation, the BfArM simply denied the ingestion of diazepam, as this drug was not mentioned in the physician’s report of the hospital. However, the hospital’s physician cannot report medications he does not know about or has not prescribed himself. The fact that a hospital report does not state every medication taken by the patient is by itself no proof that the ingestion of diazepam did not happen. In this case, the intake of diazepam was confirmed by the general practitioner of the patient. On the other hand, the BfArM argues that if diazepam really was ingested, it might not have been responsible for the incident, as the ingestion reportedly did not occur regularly. Thus, the BfArM could only identify a dechallenge pattern in the intake of kava. This is highly illogical, as diazepam was taken prior to the incident, and thus the normalization of the LFTs after discontinuation of all drugs would have to be interpreted as a dechallenge pattern to diazepam as well.

In addition, the hospital’s physician indicated that a virus hepatitis could not be excluded.

The BfArM’s arguments pointing to kava as the only possible cause of the adverse event are not plausible.

This case was classified as „possible“ by the MCA and the EMEA, and as “probable” by the BfArM. Although the dosage of Laitan at 210 mg kavalactones per day was higher than the dosage recommended by the monograph, the otherwise perfect record of kava in Oceania, the intake of potentially hepatotoxic drugs and the possibility of a virus hepatitis would rather point to other causes than kava.

4.3 BfArM-No. 99006005

Additional sources: MCA identifier no. 14, EMEA identifier no. 20
Patient: EJ, female, 33 years
Date of entry: July 26, 1999
Reported adverse effects: Bilirubinemia, hepatitis, elevated liver enzymes, liver cirrhosis.
Preparation: Kavatino (60 mg kavalactones, ethanolic extract), ingested for 4 months

in a dosage of 180 mg kavalactones per day.

Co-medication: Cisapride was taken as a gastrointestinal motility inhibitor, dosage unknown, over 4 months.

The patient was hospitalized with symptoms of an acute hepatitis. An alcoholic origin of the hepatic event was excluded. As antibodies were found, an autoimmune hepatitis was considered and treated correspondingly with highly dosed corticosteroids.

In relationship to this case, the legal representative of the product manufacturer reported further details of the incidence. The patient had developed a toxic necrotizing hepatitis with an alleged positive re-exposure. The physicians refused to offer any assistance towards the elucidation of this case. Other medications were possibly involved. The virus serology and the status of alcohol consumption is also unknown.

Assessment of the co-medication:

For cisapride, individual cases of reversible liver function impairment are labeled. Case reports can be found in the literature ([155](#); [156](#)). Referring to the known liver toxicity of the co-medication, the MCA classified the case as “not assessable”, whereas the EMEA rated it as “possible”. The BfArM evaluated the case as probable for either kava or cisapride.

4.4 BfArM-No. 00003608

Additional sources: MCA identifier no. 19, EMEA identifier no. 21
Patient: SB, female, 21 years
Date of entry: September 4, 2000
Reported adverse effects: Nausea, jaundice, fatigue, hepatitis, elevated liver enzymes, hyperhemoglobinemia
Preparation: Kavain Harras plus (30 mg D,L-Kavain + 250 mg ethanolic kava extract, corresponding to 20 mg kavalactones), dosage up to 10 tablets daily for 7 months.

Contrary to the BfArM data, the patient has since fully recovered.

Co-medication:

- Metoclopramid (Paspertin)
- Paracetamol (Acetaminophen) prior to the occurrence of icterus in unknown dosage.
- Pantoprazol (Pantozol), prior to the occurrence of icterus in unknown dosage.
- Celandine in homeopathic dosage.
- Basil extract in liquid formulation.

The intake of kava was evaluated as drug abuse.

In addition to the co-medication, there is a suspected use of illegal drugs (in the discussion: ecstasy) occurring within the same time frame as the case report. When the rumor of a possible intake of narcotics came up, the patient’s relatives promptly intervened to cause a postponement of a drug screening test, which, when finally conducted, yielded no results due to the time lapse following the incidence.

Assessment of the co-medication:

While the hepatotoxicity of celandine herb is well known, a relationship with the reported case is unlikely, as celandine was only ingested in homeopathic doses. For basil no hints on hepatotoxic events could be found.

The potential hepatotoxicity of acetaminophen is well known and might have contributed to the development of the adverse event, however the dosage of the ingested product is not known. Liver failure due to acetaminophen would have to be expected on long term (ab)use of high dosages.

For metoclopramid, increased transaminases are labeled as potential adverse events.

In the medicinal literature, at least one case of a liver failure occurring 2 days after ingestion of 40 mg pantoprazol ([155;157](#)) can be found, as well as case reports following administration of the structurally similar omeprazol (see section [9.3](#)).

In view of the possible participation of narcotics and the well-known hepatotoxicity of ecstasy ([158-160](#)), as well as the concomitant ingestion of three co-medications with known potentially liver damaging activity, a causal relationship with kava should be classified as „improbable“ for this case. Also, the liver histology from January 4, 2001 stating an „unchanged clinical picture of an autoimmune hepatitis“ does not support a causality by kava intake. Without knowledge of the possible abuse of narcotics, the MCA classified the case as “not assessable” due to the potential livertoxic effects of the co-medication. The EMEA rated it as “possible”.

4.5 BfArM-No. 00005994, Liver transplant

Additional sources: Saß et al. (2001) ([155;161](#)); MCA identifier no. 20; EMEA identifier no. 22

Patient: HW, female, 50 years

Date of entry: October 27, 2000

Reported adverse effects: disturbed general state of health, respiratory insufficiency, jaundice, elevated liver

enzymes, coma hepaticum, symptoms of hepatic encephalopathy, liver failure.

Preparation: Kava ratiopharm (60 mg kavalactones, ethanolic extract), 60 mg kavalactones per day, orally, over 6-7 months.

Co-medication:

- Antidiabetic: Glimepiride (Amaryl), 1x daily 2 mg over 7 months.
- Antidiabetic: Metformin (Glucophage S) at a dosage of 2550 mg/day over an unknown period of time, corresponding to the maximum recommended dose for this product.
- Oral contraceptive (Gravistat): ethinylestradiol 0.05 mg + levonorgestrel 0.125 mg, 1x daily, orally, for 21 years.
- Menopausal preparation (Klimonorm): 2 mg estradiolvalerat + 0.15 mg levonorgestrel, 1 coated tablet daily for an unknown period of time.
- St. John's wort for 6 months.

This case report was cited as an example for the dangers of phytotherapy in the public media ([117](#)).

The patient was hospitalized due to the occurrence of icterus and elevated liver enzymes. The liver biopsy showed a progressive necrosis of hepatic cells. After the treatment failed, a liver transplant was finally necessary.

Assessment of the co-medication:

The product label of contraceptive combinations from estrogens and progesterones states possible cases of cholestasis, anicteric hepatitis, and cholestatic icterus. The same possible adverse liver events can occur with either the contraceptive or the menopausal treatment, which are a contradiction and thus a gross hormonal overdosing. The overdosage of hormones may well have increased the rare, but still existing risk of hormonally induced liver damage.

For the antidiabetic treatment glimepiride, a sulfonylurea compound, individual cases of elevated liver enzymes, cholestasis and hepatitis are labeled, as well as for other sulfonylurea compounds such as tolazamide ([162](#)). Similarly, according to the product label metformin is known to possibly produce severe lactic acidosis with coma. Gastrointestinal disturbances, as observed in this case report, are possibly an expression of beginning lactic acidosis. As this can lead to comatose states, one should not exclude the participation of metformin in the evolution of symptoms in the present case. In addition, oral antidiabetic medications are contraindicated in liver function disorders, and may therefore have contributed to the evolution of the symptoms. Finally, several examples of adverse effects on liver metabolism by the intake of metformin can be found in the medical literature ([155;163-165](#)).

In view of the circumstances and co-medications involved, a causal association of this case to the ingestion of kava appears unjustified. Due to the known hepatotoxic properties of the co-medication the case was evaluated as “unlikely” by the MCA. The EMEA concluded a “possible”, and the BfArM

evaluated the causality of kava in connection to the intake of other enforcing agents as “probable”.

4.6 BfArM-No. 01001228 / 01001924 / 01001928

This case appears three times (with three separate case numbers) in the documentation of the BfArM (see above).

Additional sources: MCA identifier no. 26/27 (recognized duplicate entry);
EMEA identifier no. 28/29 (duplicate entry)

Patient: JR or JK, 38 or 39 years old

Date of entry: February 23, 2001 and February 28, 2001 (2x)

Reported adverse effects: Liver cell damage, hepatitis

Preparation: Laitan 100 (70 mg kavalactones, acetone extract), 70 mg kavalactones per day, orally, over the course of about 14 days.

Co-medication: Penicillin V, one day, orally.

At the time of the evaluation, no information regarding the outcome of this case was available.

Assessment of the co-medication:

The statement regarding the administration of penicillin for only one day must be called into question - if the adverse event did not immediately follow the ingestion of the antibiotic, this would have been a misuse of the drug. Since the administration of betalactam-antibiotics requires a doctor's prescription, there is an obvious connection to an acute bacterial infection, which leads to the question whether the antibiotic was the only concomitant treatment to kava.

Extensive evidence of hepatotoxic effects can be found in the literature for penicillin V (phenoxymethylpenicillin) and for structurally related penicillins (e.g. [\(166-189\)](#)). The incidence of hepatic adverse events by phenoxymethylpenicillin is rated as very rare by Goldstein et al. (1974) [\(178\)](#), Beeley et al. (1976) [\(169\)](#) and Oñate et al. (1995) [\(184\)](#). Typically, these incidents are based on an immunologic mechanism. Usually, the onset of such processes requires a much longer duration of intake than it would be usual for antibiotics. Nevertheless a hypersensitisation may occur on one occasion of the intake of antibiotics, whereas the hepatic side effect would occur on the second contact. As cross allergies are known within the group of betalactams, the second contact does not even have to be with the same compound. It is absolutely possible that the origin of the liver symptoms was associated with the concomitant administration of antibiotics.

By the MCA the case was recognized as double entry and evaluated as “not assessable”. However, the MCA does not seem to have information on the hepatotoxic risk of penicillin, although this would not have changed the classification. The EMEA did not recognize the double entry and evaluated the case as “possible” respectively “probable”.

4.7 BfArM-No. 01003950 / 01003951

These two case numbers can also be identified as a duplicate entry. This case was already referred to under section [2.3](#). As explained above, the entry of the 1993 case (BfArM no. 01003950) was added in 2001 based on an indication of the patient himself, which could not be verified with the treating physician of 1993. If there was a former kava intake, it definitely cannot have been caused by the medication stated in the line listing of the German authorities.

Additional sources: MCA identifier no. 28; EMEA identifier no. 30/32 (possible duplicate entry)

Patient: UW, female, 56 years

Date of entry: July 23, 2001

Reported adverse effects: Hepatitis

Preparation: Kava ratiopharm (60 mg kavalactones, ethanolic extract), unknown dosage and unknown duration of use.

Co-medication:

- Omeprazol (Antra MUPS), 1x 20 mg/day as needed, duration of use unknown.
- Antihypertensive: 16 mg candesartancilexetil (Blopress) until February 2001. Discontinued 5 months before the onset of the hepatitis.
- Antihypertensive with 50 mg losartan-potassium + 12.5 mg hydrochlorothiazide (Lozaar plus), 1 tablet / day, orally, taken since the discontinuation of candesartancilexetil.
- Estradiolvalerate (Estragest TTS) 2x per week in unknown dosage, transdermal therapeutic system, over an unknown duration.
- 50 µg levothyroxin, 1x daily, orally, over an unknown period of time.

- Acetylcystein, dosage and duration of use unknown.
- Throat lozenges (Dolo-Dobendan) containing 1.4 mg cetylpyridinium chloride + 10 mg benzocaine.
- Cold relief tablets (Esberitox) containing 2 mg Extractum Herba Thujae occidentalis + 7.5 mg Radix Echinaceae purpurea and Echinaceae pallidae + 10 mg Radix Baptisiae tinct. per tablet.
- Cough lozenges (Lemocin) containing 4 mg tyrothricin + 2 mg cetrimonium bromide + 1 mg lidocaine per lozenge.
- Nasal spray (Otriven) containing xylometazolin-HCl.
- Antifungal lozenges (Pimafucin) containing 10 mg natamycin.
- Gargle solution (Salviathymol): Each gram of solution contains 2 mg sage leaf oil + 2 mg eucalyptus leaf oil + 23 mg peppermint leaf oil + 2 mg cinnamon bark oil + 5 mg clove bud oil + 10 mg fennel fruit oil + 5 mg aniseed oil + 20 mg menthol + 1 mg thymol.

The BfArM lists a positive rechallenge to kava. This statement does obviously not correspond with the facts. Some background on the case was provided in a letter from the patient, who reported the hepatitis as a reaction to the administration of medications. This reaction was said to have occurred twice: the first time in 1993, the second time in 2001. Administration of the two products „Kava ratiopharm“ and „Kavain Harras N“ was mentioned. However, neither Kavain Harras N (introduced to the market in July 2001) nor Kava ratiopharm were marketed in 1993!

Possibly the patient meant to say that the 1993 case had involved the older product „Kavain Harras plus“ rather than „Kavain Harras N“, and that the new report perhaps involved „Kava ratiopharm“. However, the BfArM listing does not contain any indication of a serious incident involving „Kavain Harras plus“ from the year 1993 (which, as a serious incident, would have been reported by the physician), nor was such a case known to the manufacturer Harras Pharma. Therefore, the relationship of this older case to the ingestion of kava is highly questionable. Also, the treating physician from the year 1993 could not attribute the liver damage to any identifiable agent.

According to a personal communication with the product manufacturer's (ratiopharm) representative on September 4, 2001, the company had communicated to the BfArM a „probable“ causal relationship to kava intake in this case without further investigation. Based on the existing information, this evaluation is incomprehensible.

Assessment of the co-medication:

The co-medications were predominantly cold remedies, whose intake indicates a serious cold condition close to the occurrence of the adverse event. None of the cold preparations are suspected to have liver effects. Therefore, these medications can be taken out of the causality discussion.

Levothyroxin, as a thyroid hormone, is probably a long-term medication, however due to its lack of liver effects, a relationship with this case is also improbable.

The use of estradiol as a TTS is probably associated with menopausal complaints. Therefore, this drug is also associated with long-term use. It is conceivable that it exerts an influence on liver metabolism through sex hormones. Such effects are labeled as possible not only with oral administration but also for TTS, and confirmed by literature case reports (see section [9.2](#)).

As a further preexisting medical condition, the patient also had elevated blood pressure for which antihypertensive medications were taken. For the intake of candesartancilexetil increases of liver enzymes are labeled. Corresponding case reports can be found in the literature ([190](#); [191](#)). However, as the use of the drug was discontinued 5 months before the onset of the symptoms, the participation in the evolution of the hepatitis is unlikely. Instead, the antihypertensive treatment had been continued with a combination of losartan-potassium and hydrochlorothiazide. For losartan, increased liver values, elevated bilirubin levels and liver function impairment is labeled, whereas for hydrochlorothiazide rare cases of icterus and occasional cholecystitis are labeled and confirmed by literature reports ([96](#); [97](#)). A relationship with the reported case of hepatitis is therefore possible and - in combination with the administration of omeprazol - even probable.

For omeprazol, individual cases of hepatitis with or without jaundice, liver failure and hepatic-related encephalopathy are labeled. For a more detailed analysis of hepatotoxicity by omeprazol, see section [9.3](#). In view of the known and serious hepatic adverse events in association with the ingestion of omeprazol, as well as the possible liver value alterations due to the antihypertensive therapy and the hormone treatment, a causal relationship of this case with the ingestion of kava has to be classified as “improbable”. The classification of the MCA and the EMEA as “probable” was based on the erroneous information discussed in detail. It is not acceptable. The BfArM evaluated the report as a “certain causality to kava”, based on the supposed rechallenge from the 1993 incident. A further entry of the EMEA (identifier no. 32) referring

to a German case report with the medication “Kavain Harras” and evaluated as “unassessable” could not be attributed to any German entry and might be a duplicate entry of this case report. Except for this case report and the BfArM case no. [00003608](#) (section [4.5](#)) there was no further report with this medication.

4.8 IKS-Case No. 1999-2596

Additional sources: BfArM identifier no. 1999-2596; MCA identifier no. 15;
EMEA identifier no. 6

Patient: female, 46 years

Date of entry: August 1999

Reported adverse effects: Jaundice, liver damage, prolonged prothrombin time.

Preparation: Laitan (70 mg kavalactones, acetone extract), 140 mg/day, orally, over 4.5 months.

Co-medication:

- 80 mg propranolol (Inderal), 1 tablet/day over 4.5 months.
- Antihypertensive: 80 mg valsartan + 12.5 mg hydrochlorothiazide (Co-Diovan), 1 tablet/day over 5.5 months.

No supporting documents regarding the progress and outcome of this case are available.

Assessment of the co-medication:

For propranolol, elevated liver values and hepatitis are labeled and are literature known possible adverse events ([192-195](#)). Elevated liver values are also known to occur with the ingestion of valsartan ([196](#)), whereas thiazides can produce occasional cases of cholecystitis or icterus ([96](#); [97](#)).

In the present case, an association of causality to the co-medication is plausible. We therefore classify the case as “improbable relationship to kava”. The MCA referred to the potentially hepatotoxic co-medication, but classified this case as “possible”, as well as the EMEA.

4.9 IKS-Case No. 2000-2330

Additional sources: MCA identifier no. 17; EMEA identifier no. 8

Patient : female, 59 years

Date of entry: March 16, 2000

Reported adverse effects: Liver damage

Preparation: Laitan (70 mg kavalactones, acetone extract), 1x daily, over three weeks.

Co-medications: NSAID: 100 or 200 mg celecoxib (Celebrex) as needed.

On February 20, 2000, this patient was diagnosed with a painless icterus with elevation of bilirubin and transaminases. The alkaline phosphatase was within the normal range. On February 28 Laitan was discontinued, and 2 weeks later the liver values improved. The patient has recovered.

The IKS had classified kava as a „possible“ cause in this case. However, this association is neither supported by virus serology nor through an exclusion of an alcoholic genesis. The co-medication was not taken into consideration either.

Assessment of the co-medication:

Numerous undesired drug effects are listed for celecoxib, among which inflammatory reactions on multiple organ systems are dominant. Among others, liver function impairment, elevated liver values and hepatitis are listed and confirmed by the medical literature ([197-199](#)).

This case can easily be explained by the known adverse effects of the co-medication. Referring to the potentially hepatotoxic co-medication, the MCA and the EMEA evaluated the case as “possible”.

4.10 IKS/BfArM-Case No. 99062501

This is a case originating from Brazil, which became known to the IKS through the international CIOMS listing.

Additional sources: MCA identifier no. 12; EMEA identifier no. 18

Patient: SBS, female, 37 years

Date of entry: May 2000

Reported adverse effects: Hepatitis

Preparation: Laitan (70 mg kavalactones, acetone extract), 140 mg kavalactones/day, over two months.

Co-medication:

- Diclofenac, 150 mg intramuscular application, 2x 75 mg in May 2000.
- Contraceptive: Desogestrel + Ethinylestradiol (Microdiol), for six years.

The patient has since recovered. A rechallenge was negative for all three medications involved which allows at least the exclusion of an immunological process. However, the typical course of NSAID hepatitis (see section [9.4](#)) does not necessarily lead to a renewed hepatitis on rechallenge.

Assessment of the co-medication:

A detailed analysis of the hepatotoxic potential of diclofenac can be found in section [9.4](#). In this case the rechallenge was negative for kava as well as for diclofenac, which gives way to an exclusion of a hypersensitivity reaction, but still allows to explain the present case with a non specific transaminitis, a relatively frequently occurring class reaction well known from NSAID drugs.

In the present case a causal relationship with the ingestion of kava appears improbable. The negative rechallenge to all involved drugs rules out a hypersensitivity reaction, but not a metabolic-toxic hepatitis caused by diclofenac. The case was rated as “unlikely” by the MCA, but as “possible” by the EMEA.

4.11 BfArM-No. 01008989

Additional sources: EMEA identifier no. 34
 Patient: male, 39 years
 Date of entry: October 1, 2001
 Reported adverse effects: blood clotting impairment, hepatitis
 Preparation: Kava ratiopharm (60 mg kavalactones), 120 mg kavalactones/day, over seven months.

Co-medication:

- Interferon-beta (Avonex), intramuscular application from 1996 to September 24, 2001

There is no information on the outcome of this incident.

It can be assumed that the patient suffered from multiple sclerosis.

Assessment of the co-medication:

For interferon-beta not only hepatic adverse effects such as abnormal liver function parameters or hepatitis, but also changes in blood cell composition are labeled and confirmed by literature reports ([200;201](#)). A regular control of liver parameters is suggested for patients using this drug.

The hepatic incident occurred within a reasonable time frame to the last intramuscular application of interferon beta. A causal relationship to kava therefore seems improbable. The case report was rated as “unassessable” by the EMEA.

4.12 BfArM-No. 01010222

Additional sources: EMEA identifier no. 36
 Patient: male, 55 years
 Date of entry: not stated
 Reported adverse effects: elevated liver enzymes
 Preparation: Kavosporal comp. (10 mg kavalactones per tablet plus 100 mg of valerian extract),
 3 tablets/day over 4 weeks corresponding to 30 mg of kava extract per day.

Co-medication:

- Antidiabetic treatment: glibenclamid (Euglucon N) 7 mg/day over an unknown period of time

There is no information on the outcome of this incident.

It can be assumed that the antidiabetic treatment was a long term ingestion.

Assessment of the co-medication:

For glibenclamid, cholestasis, hepatitis and liver enzyme increases are labeled. Case reports can also be found in the literature ([202](#)). Similar effects are also known from structurally related compounds such as glimepiride or tolazamide ([162](#)).

The causality of the transaminitis in this case might well be explained with the known liver effects of glibenclamid. The case was rated as “unassessable” by the EMEA.

4.13 BfArM-No. 02001135/02002378, fatal outcome

Additional sources: EMEA identifier no. 40
Patient: female, 61 years
Date of entry: December 9, 2001
Reported adverse effects: skin rash, painful abdomen, jaundice, hepatitis, necrotic liver failure, death
Preparation: Kava ratiopharm (ethanolic extract, 60 mg kavalactones per tablet),
120 mg kavalactones/day over 3 months.

Co-medication:

- Multivitamin/mineral food supplement (Centrum), 1 tablet per day for an unknown period of time until the incident
- Ginkgo biloba extract (Kaveri), 1 tablet with 50 mg extract per day, standardized to 12.5 mg of Ginkgo flavonoids and 3 mg of terpene lactones, ingested for 13 months
- Diuretic treatment with 5 mg of bemetizid and 10 mg of triamteren per tablet (Dehydro Sanol tri mite), reportedly ingested for 7 days between November 13 and November 20, 2001
- Hymecromon (Cholspasmin forte), 800 mg per day for 10 years
- Omeprazole (Omeprazol 20 CT), 20 mg per day for 3 years

According to the data in the line listing the patient died in the course of the necrotic liver failure. There is no more data available to further elucidate the backgrounds of this case report.

Assessment of the co-medication:

Whereas the multivitamin and the ginkgo preparation appear inconspicuous, as no liver effects are known for such preparations, for the diuretic drug combination, rare cases of icterus are labeled as possible adverse events.

The indication of hymecromon is impaired bile flow or inflammatory diseases of the bile ducts. This condition seems to have preexisted for at least 10 years and might have had an influence on the evolution of the present case, even though hymecromon itself does not seem to have adverse liver effects.

Omeprazole is widely known to produce liver function impairment, the incidence of hepatic adverse reactions from omeprazole was calculated to 2.1 cases in 100.000 applications ([75](#)). For a more detailed analysis see section [9.3](#).

The incident happened within a sensible time frame of the intake of omeprazole. Thus, the case may well have been caused by the concomitant treatment. The BfArM discarded omeprazole as a possible cause as this medication was a long term treatment without any previous incident. In consequence, following the assessment of the hospitals' physicians, the case was evaluated as "probable" by the BfArM. The EMEA assessed the case as "possible".

4.14 BfArM-No. 02001776

Additional sources: EMEA identifier no. 42
Patient: male, 27 years
Date of entry: unknown
Reported adverse effects: sweating, anxiety, paresthesias, decoloured feces, pathologic urine
Preparation: Kavacur (ethanolic extract, 60 mg kavalactones per tablet),
120 mg kavalactones/day over an unknown period of time.

Co-medication:

- Anti-HIV treatment nevirapine (Viramune) in unknown dosage and duration
- Anti-HIV treatment stavudine (Zerit) in unknown dosage and duration
- Anti-HIV treatment lamivudine (Epivir) in unknown dosage and duration

The outcome of this case is unknown. Judged by the data provided in the line listing, it is even debatable if an adverse hepatic reaction occurred. Only the discoloration of the feces and the non specified pathologic urine points this way.

Assessment of the co-medication:

Only kava was rated as a suspected drug in this case. In view of the known hepatic adverse effects of the HIV treatment this is not acceptable.

For nevirapine, increased liver values and hepatitis with fatal outcome are labeled. According to the label stavudin may cause pancreatitis, liver function impairment, hepatitis and liver failure, but also anxiety

and sweating as reported for this case. Finally, for lamivudin also elevated liver enzymes and pancreatitis are labeled as possible adverse effects. These potentially severe hepatic effects can also be found in corresponding publications (e.g. (158;203-216)). Elevations in liver enzyme levels have been associated with the use of nonnucleoside reverse transcriptase inhibitors. In addition, mortality due to liver failure has increased during the past 10 years (209). Consequently, the European Medicines Evaluation Agency's scientific committee issued a warning regarding the potential hepatotoxicity of nevirapine (209). The most frequent hepatic abnormality is an elevated GGT level (209).

The reported reaction can easily be explained by the known liver effects of the HIV treatment. The case was rated as "unassessable" by the EMEA.

4.15 BfArM-No. 02002090/02002836

Additional sources: EMEA identifier no. 45
Patient: N.A., female, 26 years
Date of entry: February 13, 2002
Reported adverse effects: reversible increase of transaminases
Preparation: Kavasedon (ethanolic extract, 50 mg kavalactones per tablet),
4-6 capsules overall within one week.

Co-medication:

- Sulfasalazin (Azulfidine RA) 500 mg/day for 5 months
- Diclofenac-Colestyramin (Voltaren Resinat) 140 mg per capsule, corresponding to 75 mg Diclofenac-sodium, one tablet per day for 5 months
- Butylscopolaminium bromide (Buscopan), 10 mg per tablet, occasionally
- Medroxyprogesterone acetate (Depot-Clinovir) intramuscular depot injection for contraception, long-term treatment
- (S)-Omeprazole (Nexium MUPS), 40 mg/day, probable long-term ingestion

The patient has fully recovered.

In Juni 2001 a Morbus Bechterew was diagnosed, leading to the prescription of sulfasalazine and Diclofenac. Omeprazole was prescribed in connection to symptoms related with the patient's obesity. As required for the medication with sulfasalazine, liver function parameters were regularly assessed by the patient's physician. On October 16, 2001 no deviation in the liver parameters was detected.

Due to a stress situation with a pending exam the patient ingested 4-6 capsules of a kava product within one week in the end of November. The following week, she complained about unspecific abdominal pains. Due to a distortion of an ankle a surgic intervention had been scheduled for the first week of December. On December 2, the patient presented herself at the hospital for a check on her gastrointestinal complaints. Routinely, the liver function parameters were taken, showing an elevated SGPT value of 80 U/l. LDH was in the normal range.

The patient's physician reanalyzed the liver values on December 4, 2001. The elevated transaminases were confirmed: SGOT was 220 (normal range: <19 U/l), SGPT 572 (normal range: <23 U/l), γ GT 174 (normal range: 6-28 U/l). Lipases and amylases were in the normal range.

The patient was admitted at the hospital with a suspected toxic hepatitis on December 6. She was dismissed with normal values on December 21.

On admittance to the hospital the kava product was considered as the causal factor because of the discussion of the drug safety protocol in the media. Other possible causes were not discussed. The routine examination on admittance showed a good general health state without neurologic, cardiac or pulmonary deviations. Liver sonography was inconspicuous, liver and spleen were not palpable. The analysis of blood and liver parameters showed the following deviations: GPT 306 U/l, γ GT 72 U/l, alkaline phosphatase 163 U/l, LDH 235.

SGOT and bilirubine were within the reference range, as well as all measured blood parameters. The virus serology was negative for hepatitis A, B and C, EBV and CMV. Autoimmune antibodies were not detected.

Compared to the transaminase values taken two days earlier the values had already started to decrease, in accordance to a reversible transaminitis.

All medication was discontinued in the hospital. The liver values continued to return to normal until dismissal.

Due to the still pending university exam the patient avoided a renewed intake of her antirheumatic therapy

until the date of the exam on January 25, 2002. After the exam, the medication with sulfasalazine and Diclofenac was restarted, in April 2002 also omeprazole was taken again.

The rechallenge with sulfasalazine and diclofenac first led to new gastrointestinal complaints. Again, the liver function parameters were measured on February 11, 2002. All blood values and transaminases were well within the normal range. The sonographic examination was inconspicuous, the medication was continued.

At the time of the final assessment of this report omeprazole had been newly taken for a few days, reportedly without any adverse effect.

Assessment of the co-medication:

Butylscopolaminium bromide is inconspicuous regarding the liver effects. There seem to exist no reports on hepatotoxicity in the medicinal literature.

Principally, icterus and anicteric hepatitis are labeled as potential adverse effects of contraceptives (see also section [9.2](#)). However, the hepatic adverse effects rather seem to be correlated with the estrogen component of contraceptives than with the progesterone component. Specifically for **medroxyprogesterone** the risk of hepatic adverse events seems very limited. On the contrary, clinical and pharmacological studies indicate a hepatoprotective effect of medroxyprogesterone in the treatment of liver cirrhosis ([217-221](#)). Within the scope of a one year case control study in 357 patients occasional elevations of bilirubin and decreases of alkaline phosphatase were observed, whereas the transaminases remained unchanged ([222](#)).

The missing influence of medroxyprogesterone on transaminases as well as the typically observed bilirubinemia with jaundice are not reflected in the data of the present case report. Here, only the transaminases were elevated. Thus, a causality of medroxyprogesterone in this case is improbable.

(S)-Omeprazole is the (S)-isomer of omeprazol. In comparison to racemic omeprazol the hepatic metabolism of the (S)-form is less pronounced, even though both isomers yield the same hepatic metabolites ([223;224](#)). Correspondingly one can expect the hepatic adverse events observed with racemic omeprazole to occur with the (S)-isomer also. As discussed in section [9.3](#), case reports of liver failure and hepatitis related to omeprazole or related compounds are known from the medicinal literature. Elevated transaminases under omeprazole often return to normal values without discontinuation of the therapy ([225](#)). Principally, the reversible transaminitis observed in this case report is consistent with the known liver effects of omeprazole. The known facts would fit to the mechanism of an idiosyncratic-metabolic reaction, which can occur even after long-term ingestion of the drug. The case reports of Navarro et al. (1997) ([226](#)) and two cases described by Koury et al. (1998) ([227;228](#)) are very similar to the present case in course and symptoms: there was no clinical correlate, a negative virus serology and an inconspicuous sonography, at the same time the transaminases were elevated and returned to normal after discontinuation of omeprazole. A renewed increase of transaminases on rechallenge is not obligatory, in some cases the reaction did not reoccur at all or only after a long delay. All taken together, the observed liver reaction may well have been caused by omeprazole or diclofenac (see below).

For **sulfasalazine** gastrointestinal complaints are labeled, as well as individual cases of hepatitis. The gastrointestinal symptoms on renewed intake of sulfasalazine in January 2002 are consistent with the overall picture of adverse reactions of this compound. Hepatic adverse events with sulfasalazine are well known. An analysis of the literature cases can be found in section [9.5](#). As liver reactions to sulfasalazine mostly follow an idiosyncratic-immunologic course, a participation in the onset of the present case seems improbable. Hepatic sulfasalazine reactions usually occur after 14-21 days of drug intake, and are characterized by a hypersensitization. On rechallenge the liver reaction usually reoccurs within 24 hours and follows a more fulminant course. If the incident in December 2001 had been a hypersensitization against sulfasalazine, the reaction would have reappeared after the renewed intake in January 2002. However, a non-immunologic reaction cannot be excluded and is still a possible explanation in the present case.

Colestyramin was part of a combination product with diclofenac. On treatment with this compound, initial increases of the alkaline phosphatase and transaminases are possible. However, the duration of intake of approximately five months would not count under initial effects any more. In addition, no case reports with hepatic adverse events were found in the medicinal literature. Colestyramine probably had no part in the evolution of the observed transaminitis.

Diclofenac counts among the NSAIDs, and for those a multitude of case reports of hepatic adverse events can be found in the literature (for details see section [9.4](#)). Especially transaminitis was recognized as a

class reaction by the FDA (76). Besides unspecific transaminitis, hepatitis of immunologic origin is known to occur in some cases. However, the reexposition to diclofenac in January 2002 without reoccurrence of the symptoms allows to discard the possibility of a hypersensitivity mechanism. On the other hand, the course of the incidence is absolutely consistent with a NSAID transaminitis, up to the observation of gastrointestinal symptoms in the beginning of the incident (229). Such reactions can still occur several months after the onset of the treatment, and are characterized by a mild evolution of the hepatitis, a rapid normalization of the liver values and the lack of a spontaneous reaction on rechallenge. Renewed symptoms were observed six weeks after the restart of the therapy, but do not necessarily occur. Only 4-6 capsules of **the kava product** were taken by the patient in the course of one week (no more than 50 mg of kavalactones per day). Reportedly this was the first contact ever of the patient to kava. The amount of kavalactones ingested and the time frame of the incident cast serious doubts on the participation of kava in this case. An intrinsic toxicity can be excluded for kava, as this would have been apparent from the centuries of experience with the regular intake of much higher dosages. Intrinsic toxicity is obligate and reproducible in animal experiments. Kava extract was examined in several toxicity studies (82-88), some of which also included liver parameters. In a six month study of chronic toxicity Sorrentino (88) examined the effects of 73 mg kavalactones per kg body weight in dogs and rats on SGOT and SGPT values, without finding any changes. Gebhardt (83) examined the effects of the total extract as well as of the six major isolated kavalactones in cell culture experiments on rat and human hepatocytes. Again, the hepatotoxicity was well above the maximum applicable concentration range in the experiment. An idiosyncratic-metabolic toxicity, where the adverse hepatic effects would be due to an accumulation of a toxic metabolite, was never observed in the South Pacific, where much higher dosages are regularly taken than in German drugs (89). However, such a mechanism cannot generally be ruled out, as it would depend on the individual and genetically determined enzyme distribution in cytochrome P450 oxidases. Even though toxic effects through a genetically determined lack of a given subtype of cytochrome P450 cannot be ruled out, corresponding effects have never been observed in post marketing surveillance studies on meanwhile more than 15.000 patients overall.

In addition, in the present case this mechanism cannot have been the cause of the incident, as an idiosyncratic mechanism of either type, metabolic or immunologic, would require a longer duration of ingestion and - in the case of metabolic disorders - a higher dosage for an adequate accumulation of the supposed toxic metabolite. Neither was possible with the intake of only 4-6 times 50 mg of kavalactones. The evolution of the present incident and the laboratory parameters point to an idiosyncratic-metabolic hepatotoxicity, caused either by omeprazole or - more probable - by diclofenac.

The BfArM did not follow this argumentation, evaluating this case as a “probable” causality to kava. The BfArM states that adverse liver effects of butylscopolaminium bromide and medroxyprogesterone acetate are not known or improbable in this case, a statement which does not contradict the analysis given above and handed to the BfArM in the evaluation of the case report. Otherwise the BfArM pointed to the negative challenge-dechallenge-rechallenge pattern of the co-medication, which would leave only kava as a suspected medication. The evidence regarding NSAID transaminitis and the lack of a typical rechallenge pattern for such drugs was simply discarded, which is unacceptable as it appears arbitrary.

The case was rated as “unassessable” by the EMEA, however based on the erroneous information of an intake of kava in a dosage scheme of 6 capsules per day.

4.16 FDA Case no. 14723

Additional sources: EMEA identifier no. 51
Patient: female, 44 years
Date of entry: March 9, 2001
Reported adverse effect: elevated liver enzymes
Preparation: Combination of kava and vitamin B1, B6 and niacin, unknown dosage
Concomitant medication:

- Anticoagulation: 5 mg of warfarin (Coumadin), unknown application time.
- Major tranquilizer: Citalopram hydrobromide (Celexa).
- NSAID: Celecoxib (Celebryx) in unknown dosage and application time.
- Pain relief: Oxycodon (OxyContin) in unknown dosage and application time.
- Estrogen in unknown dosage and application form and time.

As a preexisting medical condition a Marfan-Syndrom was indicated. A surgical replacement of an aortic valve and the removal of a thorical aneurism was stated. The patient was hospitalized due to increased liver enzymes.

Assessment of the co-medication:

For the pain relief oxycodon no adverse effects on the liver are labeled, though spasms of the bile ducts with pressure increase in the ductus pancreaticus are known to occur. This mechanism, however, will not have contributed to the evolution of symptoms in the present case report.

Estrogen has to be considered a long time application. For a more detailed analysis of estrogen hepatotoxicity, refer to section [9.2](#). With contraceptives mainly producing jaundice in cases of rare hepatic adverse events, the participation in the evolution of this case is unlikely.

Increases of liver enzyme activity are labeled for the antidepressant citalopram.

For warfarin, hepatitis, liver function impairment, jaundice, elevated liver enzymes and pruritus are labeled as possible adverse effects. Case reports can be found in the literature ([230-233](#)). Ammon mentions increases of liver enzymes under warfarin therapy as an occasionally observed reaction, which is usually reversible ([234](#)).

Celecoxib has a multitude of labeled adverse effects, and among these inflammations in multiple organs dominate. Among others hepatitis, impaired liver function and elevated liver enzymes are listed and confirmed by the literature ([197-199](#)).

With the intake of citalopram, warfarin und celecoxib possibly leading to elevated liver enzymes, the observed adverse event could easily be explained by any the these three drugs. Thus, kava probably had no part in the evolution of the symptoms. In spite of the hepatotoxic potential of the concomitant treatment, this report was evaluated as “possible” by the EMEA.

4.17 FDA Case no. 15035/15274 (liver transplant)

Additional sources: EMEA identifier no. 53

Patient: female, 45 years

Date of entry: August 17, 2001

Reported adverse effect: jaundice, pruritus, cholestatic hepatitis, liver transplant

Preparation: Combination of 250 mg of kava extract, standardized to 30% of kavalactones (corresponding to 75 mg of kavalactones), hop, German camomile, passion

flower,

each in unknown dosage. Two tablets per day corresponding to 150 mg of kavalactones were taken for 2-4 months.

Comedication:

- Reflux medication: Rabeprazol-sodium (Aciphex) in unknown dosage and application time.

In the course of the event, the patient had to undergo liver transplant. The outcome of the case is not known.

The British MCA reported on a negative testing for hepatitis virus A-C and a very low alcohol consume on rare occasions.

Assessment of the comedication:

As a preexisting medical condition, a reflux was mentioned, explaining the intake of the reflux medication Rabeprazol-sodium. A long term treatment may be assumed. For the structurally related omeprazol, the medicinal literature has cases of hepatitis and liver failure ([226-228 ;235](#)) (see also section [9.3](#)). Not being marketed for the same length of time, for rabeprazol-sodium one case of a fulminant liver failure was reported, where the drug was taken in combination with the antifungal drug terbinafine ([236](#)).

As the reflux treatment is principally a possible alternative cause for the observed adverse reaction, the conclusion of the causality of kava would appear doubtful without further examination of the case. The assessment of the EMEA was “probable”.

4.18 FDA Case no. 14538

Additional sources: EMEA identifier no. 50

Patient: female, 60 years

Date of entry: November 24, 2000

Reported adverse effect: fatigue and increase of liver enzyme activity
Preparation: „kava“ in unknown dosage and application time
Concomitant medication:

- Chaparral-leaves in unknown dosage and application time.
- Licorice in unknown dosage and application time.
- Cytostatic: Capecitabine (Xeloda) in unknown application form, dosage und application time.
- Cytostatic: Fluorouracil (Eniluracil) in unknown application form, dosage and application time.

The patient was treated by irradiation and chemotherapy with the cytostatics fluorouracil and capecitabin due to a locally advanced rectal cancer. As a former surgical intervention a thoracotomy 22 years ago and a lumbar disc surgery were stated.

Assessment of the comedication:

As liquorice has no known adverse liver effects, it can be excluded from the assessment.

In the literature some cases of liver function impairment by the cytostatic fluorouracil can be found (e.g. (237-240)). For the corresponding drugs possible liver damage is labeled.

For capecitabin no case reports of side effects on the liver could be found in the medicinal literature. As indicated by the producer in the internet (<http://www.rocheusa.com/products/xeloda>), in clinical studies aimed on the proof of efficacy several types of adverse effects on the liver were found when the drug was given as the only medication, even more so in combination with other cytostatics. The producer mentions increases of liver enzymes and liver failure, hepatic coma and hepatotoxicity.

An unwanted support of the inherent liver toxicity of cytostatics can be produced by extracts of leaves the desert plant „chaparral“. This natural remedy, taken as an antioxidant, was the cause of a multitude of reports on possible hepatotoxicity in the United States and Mexico (241-250).

Due to the known liver toxic potential of the concomitant medication, especially the cytostatic treatment in combination with a chaparral extract, the connection of the observed increase of liver enzyme activity with the intake of a kava product seems highly unlikely, which is in accordance to the assessment “unlikely” by the EMEA.

4.19 FDA Case no. 10257

Patient : female, 70 years

Date of entry: May 18, 1995

Reported adverse effect: elevated liver enzymes

Preparation: Herbalife K8 with “kava kava 40 mg” and “Biokawa 20 mg” containing 14.3% Kavain, 3 units per day for an unknown period of time.

Comedication:

- Propranolol (Inderid) for 15 years
- Aspirin for 15 years
- Warfarin (Coumadin)
- Lisinopril (Zestril)
- Fish oil
- several vitamins

The patient was hospitalized for at least due to stroke and a prolapsed mitral valve. γ GT was 125-212, SGOT 66-99, all other values were in the normal range.

The medication allows the conclusion of a long existing coronary heart disease as a preexisting medical condition.

Assessment of the comedication:

For propranolol, elevated liver values and hepatitis are labeled and literature known possible adverse events (192-195).

For Aspirin, impaired liver function in individual cases is labeled. In addition, drug is known to produce increases of transaminases rather frequently (3-5% of the patients taking aspirine, of those cases 3% severe and potentially life-threatening) (78-80), the adverse reaction even being considered a class reaction for NSAID (see section 9.4).

For warfarin, hepatitis, liver function impairment, jaundice, elevated liver enzymes and pruritus are

labeled as possible adverse effects. Case reports can be found in the literature ([230-233](#)). Ammon mentions increases of liver enzymes under warfarin therapy as an occasionally observed reaction, which is usually reversible ([234](#)).

Lisinopril can also cause liver function impairment, hepatitis and cholestatic icterus, there are even fatal outcomes labeled in rare cases. Liver function disorders require an immediate discontinuation of the therapy. Corresponding case reports can be found in the literature ([151-153](#)).

The ingestion of highly dosed fish oil is known to produce transient elevations of the liver enzymes as a non-pathological reaction pattern.

It can be assumed that the vitamins taken by the patient had no part in the incident.

From the case report it is unclear whether the elevated liver function parameters had existed before the hospitalization, and for how long. There is no indication of an exclusion of an alcoholic genesis as well as a virus and autoimmune antibody serology. In addition, all of the medications taken by the patient can by themselves cause elevated liver enzymes. Thus, a participation of a relatively small dosage of kava in the event seems rather unlikely.

4.20 FDA Case no. 15466

Additional sources: EMEA identifier no. 58
Patient: female, 39 years
Date of entry: February 2, 2002
Reported adverse effect: Fatigue, flu-like symptoms, jaundice, hepatitis
Preparation: Nature's Way Kava extract (128 mg per unit, standardized to 70 mg of kavalactones) plus Celestial Kava tea, dosage scheme and duration of intake not given.

Comedication:

- undefined OTC drugs
- Asthma medication: Salbutamol (Albuterol)
- Allergy treatment: Diphenhydramin (Benadryl)
- Tetracyclin two episodes, one right before episode

As a preexisting medical condition asthma and allergies against dogs and dust were stated. The liver function parameters returned to normal within four weeks, a hospitalization was not necessary.

Assessment of the comedication:

Salbutamol and diphenhydramin appear as inconspicuous, as no hints on hepatic adverse reactions could be found. In contrast, tetracycline does provoke hepatic adverse effects reproducible in pharmacological and toxicological experiments ([251-271](#)). The intake of tetracycline was stated on two occasions. As the liver episode started right after the second intake of tetracycline, a hypersensitization against the antibiotic might easily explain the incident. Unfortunately, the data is insufficient as to prove this theory.

A part of the concomitant medication is unknown and cannot be evaluated. In addition, there is no indication of an exclusion of an alcoholic genesis as well as a virus and autoimmune antibody serology. With the known potential hepatotoxicity of tetracycline in mind, a causality of kava seems rather unlikely. However, the causality of kava was evaluated as "possible" by the EMEA.

4.21 MCA case report (EMEA identifier no. 2)

Patient : female, age unknown
Reported adverse effect: jaundice, increased LFTs
Preparation: Kava extract 3x 150 mg/day (unknown content of kavalactones) for 2 months.
Comedication:

- Fluoxetine (Prozac)

At the time of the compilation of the data by the EMEA, the reaction was still ongoing. The patient was hospitalized for seven weeks, liver biopsy was reported as "pending".

Assessment of the comedication:

Fluoxetine is known to produce liver toxicity ([158;272-280](#)). Among 3000 patients treated with fluoxetine in clinical trials, elevated aminotransferases developed in approximately 0.5% ([279](#)). Through the Spanish

System of Pharmacovigilance, until April 1999 in total 493 cases with suspected adverse events due to fluoxetine were assembled. Six of these reports described acute hepatitis, and five asymptomatic increase in serum transaminases ([273](#)). In addition, animal studies have shown hepatocellular changes in mice ([281](#)). For closely related substances, reports of hepatotoxicity were also published, e.g. for paroxetine ([282-284](#)) and sertraline ([285](#)).

The available data does not allow the conclusion of a causality by kava, as alternative explanations are present in the form of fluoxetin. The EMEA evaluated the case as “possible”.

4.22 Literature case: Kraft et al. (2001), Liver transplant

This case can be classified as drug abuse. It was cited as an example for the inherent dangers of phytotherapy in the German public media ([117](#)).

Additional sources: Kraft et al. (2001) (1); MCA identifier no. 29;
EMEA identifier no. 5

Patient: female, 60 years

Date of entry: September 7, 2001

Reported adverse effects: Fulminant liver failure with liver transplant

Preparation: Antares (120 mg kavalactones, ethanol extract), 480-1200 mg kavalactones / day

for over one year with non-prescribed dosage increase.

Co-medication:

- Etilefrine-HCl, occasionally for orthostatic dysregulation.
- Diuretic: Piretanide (Arelix) for recidivating edemas due to ovariectomy.

The patient was hospitalized due to progredient exhaustion, weight loss and icterus with dark coloration of the urine and jaundice. At the time of hospital admission, the symptoms had been present for 14 days. The patient had suffered from pulmonary embolism 11 years ago, with cardiopulmonary reanimation, and 21 years ago, she had an ovariectomy and cholecystectomy. For 8 years, she suffered from increasing depression.

According to the patient’s statement, alcohol consumption was negative. Transaminases and bilirubin were strongly elevated, and there were signs of a beginning kidney failure. Assays for hepatitis A, B and C, HIV, CMV, EBV, HSV as well as for Varicella-Zoster-Virus were negative. The sonographic picture was inconspicuous. There were no indications of an obstruction of the bile ducts. The histological examination revealed an extensive necrosis of the hepatic cells with intrahepatic cholestasis.

Progressive encephalopathy and pulmonary failure requiring intubation, as well as rising bilirubin levels, made a liver transplant necessary.

Based on the cases reported by [Strahl et al. \(1998\) \(2\)](#) and [Escher et al. \(2001\) \(72\)](#), [Kraft et al. \(2001\) \(1\)](#) suspected a connection with an immunological event. However, [Escher et al.](#) did not indicate a rechallenge, and the data available from this case do not allow the conclusion of an immunologic hypersensitisation as a contributing factor. Also, the lymphocyte transformation test is missing, although [Escher](#) participated in the studies by [Russmann et al.](#) wherein a hypersensitisation to kava could be detected for the cases reported by [Strahl et al.](#) and the IKS case [2000-0014 \(70\)](#).

Finally, according to [Kraft et al. \(2001\)](#), a contribution from the co-medication (piretanide) cannot be excluded ([1](#)). The product label indicates the possibility of cholangitis with intrahepatic cholestasis and increased transaminases ([286](#)).

It is apparent that kava was not used according to the label recommendation. The dosage prescribed by the physician exceeded the recommended daily dosage by a factor of at least 4, and the administration of kava is contraindicated for major depression. Information from relatives revealed that the patient took extra doses *ad libitum* in addition to the already overdosed regimen. Some statements indicated the use of up to 10 tablets per day.

All taken together, a causal relationship of kava still remains unclear. Even if the abuse of kava should have contributed to the development of the incident (which is mere speculation), one would not be able to draw a conclusion for the intake of kava within the recommended dosage scheme.

The MCA and the EMEA rated the case as “possible”.

5. Doubtful Causality

Six of the known suspected cases of kava-related hepatic side effects cannot simply be negated. However, a conclusive correlation to kava intake is not possible. In the following cases no comedication, or only preparations without a known hepatotoxic potential, are listed. Based on the experiences from the previously listed cases, however, it cannot be taken for granted that no suspicious comedication was taken. In addition, personal experience with the handling of spontaneous reports of adverse events shows that crucial information is often not communicated without closer inspection of the case, or not obtainable at all due to poor cooperation of the patient and often also of the physician. Unfortunately, this creates an overestimation of the inherent risk of a drug by producing rather too many cases where the causality is assessed as highly probable because alternative causes cannot be evaluated.

5.1 BfArM-No. 94006568

This case was reported by a hospital.

Additional sources: SWISSMEDIC (IKS no. 94/0259); WHO case no. 94 159 702-2;
MCA identifier no. 5; EMEA identifier no. 13

Patient: LM, female, 68 years (according to CIOMS 69)

Date of entry: BfArM: September 14, 1994/ IKS: August 16, 1994

Reported adverse effects: Jaundice, cholestatic hepatitis

Preparation: Laitan 100 (70 mg kavalactones, acetone extract) in a dosage of 210 mg per day,
orally for 2 years

Co-medication:

- St. John's wort extract (Neuroplant forte), 2 coated tablets/day, orally for 1 year.
- Also known to the IKS: aluminum hydroxide (Maaloxan), orally if needed.

The patient made a full recovery.

The patient was admitted to hospital with an unspecific icterus, hyperbilirubinemia and elevated values of SGOT, SGPT and γ -GT. The liver biopsy showed severe toxic-cholestatic liver damage.

Neither St. John's wort nor aluminum hydroxide are known to have adverse liver effects. Based on the evaluations of the Institute of Pathology at the Kassel City Hospital, the histological image was consistent with an immunologically triggered hypersensitivity reaction, which led to an idiosyncratic damage of hepatic tissue. The biopsy did not confirm a drug-induced toxicity, an autoimmune process was not excluded.

Normally, the latency period for drug induced idiosyncratic toxic hepatitis is about 50-90 days. The kava preparation was used for over 2 years, and the St. John's wort remedy for over one year; well beyond the expected latency period of hypersensitisation against either plant. In the Swiss documentation, the causality of kava was therefore evaluated as "improbable", even though the Laitan dosage was above the German monograph recommendation. The MCA and the EMEA classified the report as "possible", as well as the BfArM, the latter due to missing indications of alternative medications with potential liver toxicity.

5.2 BfArM-No. 97002825 / 97003551

The common features of the BfArM cases no. 97002825 resp. 97003551 were already discussed in section [2.1](#). Both listings of the BfArM, however, show different entries with regard to the duration of use: in one report, the product “Phyto-Geriatrikum” was taken over a period of 6 months; in the other report for more than 2 years.

Additional sources: MCA duplicate identifier no. 7/8; EMEA identifier no. 15

Patient: SM, female, 72/75 years

Date of entry: May 5, 1997 / June 12, 1997

Reported adverse effects: Hepatic cell damage, jaundice, cholestatic hepatitis

Preparation: Phyto-combination product (Phyto-Geriatrikum) with 50 mg pancreatin + 30 mg bromelain + 20 mg ginseng root extract + 30 mg papain + 25 mg ethanolic kava extract with about 0.6 mg kavalactones + 30 mg devil’s claw root extract + 20 mg hawthorn flower and leaf extract, dosage unknown, orally for an unknown duration.

Co-medication:

- Vitamin supplement (Eunova); composition and dosage unclear: 400 mg DL- α -tocopherol or 4000 I.E. retinole acetate + 2 mg vitamin B1 + 2 mg vitamin B2, 15 mg nicotinamide + 6 mg Ca-pantothenate + 2 mg vitamin B6 + 1 μ g vitamin B12 + 70 mg vitamin C + 100 I.E. vitamin D3 + 3 mg vitamin E + 10 μ g biotin + 10 mg rutoside + 20 mg FeSO₄ + 0.8 mg CuSO₄ + 1 mg MnSO₄ + 0.4 mg ZnO + 60 μ g Na-molybdate + 5 mg K₂SO₄ + 15 mg MgSO₄ + 147.3 mg CaHPO₄).
- Prednisone, orally, 5 mg per day, long-term application with reportedly continued ingestion

The outcome of this case was not clear at the time of evaluation in 1997.

Due to insufficient information, the entries in the category „co-medication“ could indicate a multivitamin-multimineral mixture or a vitamin E preparation. Within the normal dosage range of both products, no liver hepatotoxicity should be expected. In connection with a high dosage vitamin A regimen, a control of the liver values is recommended. The dosage recommendation for Eunova is 2 coated tablets/day, corresponding to 8.000 I.E. vitamin A. This is within a relevant range of potentially hepatotoxic effects, especially when overdosed ([287](#)).

For the corticosteroid prednisone, no adverse effects on the liver are labeled.

Phyto-Geriatrikum is a multicomponent-mixture which contains, in addition to other extracts and enzymes, 25 mg kava extract. Based on information from the manufacturer, the extract is standardized to 2-3% kavalactones. The calculated single dose is therefore about 0.6 mg kavalactones. There are no other known facts supporting kava as a cause of the observed adverse event. Based on the poor documentation, however, it is not possible to prove the contrary. Without exclusion diagnostics for organic causes (e.g. gall duct obstruction), virus serology, and alcohol abuse, a causality based on kava cannot be established. The MCA identified the case as a double entry and classified it as “not assessable”, whereas the EMEA came to the result “possible”.

5.3 BfArM-No. 00008627, Liver transplant with fatal outcome

This case was discussed in the public media as an example for the severe inherent dangers of medication with plant derived drugs ([117](#)). However, even though the patient really existed and the selected facts presented to the public were consistent with the known circumstances, considerable doubt concerning the correct citation of the backgrounds was raised by the fact that the patient who really had died from complications of the liver transplant was presented with a reportedly private photography. Some days later, the very same lady presented in the photography made a reappearance on the German TV and in a newspaper, presenting another story of a liver failure caused by kava, which could not be backed by the case reports in the line listings (see section [3.4](#)).

Additional sources: Brauer et al. (2001) ([117](#) ;[155](#)); MCA identifier no. 21;
EMEA identifier no. 23

Patient: DS, female, 22 years

Date of entry: December 27, 2000

Reported adverse effects: Leukocytosis, positive C-reactive proteins, liver cell damage, liver necrosis, elevated liver enzymes, bilirubinemia, fatigue, jaundice, fulminant liver failure, liver coma

Preparation: Antares (120 mg kavalactones, ethanol extract), 240 mg kavalactones/day for 4 months

Co-medication:

- Migraine medication: 7.2 or 14.5 mg rizatriptan-benzoate (Maxalt), if needed.
- Contraceptive: norgestimate + ethinylestradiol (Pramino).
- Prior use of another contraceptive: ethinylestradiol + dienogest (Valette).
- Possibly an unknown NSAID for pain relief.

In the abstract publication by Brauer et al. 2001 ([155](#)), the indication for the use of kava was „endogenous depression“. There is considerable doubt concerning this detail, since kava is contraindicated for endogenous depression. However, this surely had no influence on the course of the case itself.

According to the author of the case report, a more concise publication was submitted with additional details. In a personal communication we were told that the case details are a clearcut proof for the causality of kava, as the patient was perfectly healthy prior to the hepatic incident, still lived with her parents and did not consume alcohol and did not smoke.

When the patient was hospitalized, the jaundice had already been developing for some days. During this time, the medication was continued. The patient presented herself not because of the extreme bilirubiemia, but because of persisting fatigue and nausea. Besides the already manifest jaundice, increased liver enzymes were noted on hospital admittance. Bilirubin was 10fold the normal values. Although the medication was immediately discontinued, the patient developed a fulminant liver failure within three days, had to be intubated due to respiratory failure, and suffered from cardiac failure and encephalopathy. The toxicological screening, including alcohol and virus serology for hepatitis A, B and C, was negative. The biopsy showed pronounced necrosis of the hepatic tissue and damage to the parenchyma. The case resulted in a liver transplant, which was further complicated by a postsurgical CMV-infection and an intrahepatic arterial stenosis. The liver biopsy revealed a complete necrosis of liver tissue, thus no histologic indications for the mechanism of the liver failure could be found.

After liver transplant surgery, the patient developed an aspergillus infection (not a virus hepatitis as stated by the BfArM's reasoning for the ban of kava products) due to the immunosuppression, which finally led to her death.

Assessment of the co-medication:

The use of rizatriptan is known, however there are no adverse liver effects labeled for this drug. Another pain relief medication was mentioned by the author of the case report, possibly a NSAID. The hepatotoxic potential of such compounds is well known and discussed in section [9.4](#). However, without more concise information one can only speculate on the participation of such compounds in the causality of the present adverse event.

The possible hepatotoxic effects of contraceptives are discussed in section [9.2](#). The strong jaundice on hospital admittance, which according to a personal information obtained from the author had already persisted for several days prior to hospitalization, leaves some doubt concerning the effects of the contraceptive treatment, as estrogen/progesterone combinations are known to produce cholestatic icterus in rare cases (see section [9.2](#)).

Concerning the statement of a perfect health prior to the incident, there are some open questions. An investigation with the treating physician revealed a former hepatic incident in 1997. Even though a drug related incident was supposed, the cause of this former incident was reportedly never identified. As the patient was an employee of a pharmacy (confirmed by an article in the gazette "Stern", where the case was presented to the public as an example of the inherent dangers of kava ([117](#))), she had access to potentially hepatotoxic preparations without the need of a medical prescription. This was suggested as a possible cause of the 1997 incident. Thus, possibly other drugs than kava played a role, in addition to the listed

comedication.

The MCA referred to possible hepatotoxic effects of the contraceptive treatment, and classified the case as “possible”, as well as the EMEA. Due to the time frame of the occurrence of the symptoms in connection to the intake of a kava product, the BfArM evaluated the causality as “possible - probable”.

5.4 FDA case no. 15281

Additional sources: EMEA identifier no. 55

Patient: female, 27 years

Date of entry: December 27, 2001

Reported adverse effects: Jaundice, nausea, vomiting, ascites, abdominal pain, dark urine, elevated liver enzymes, possibly stage 3 hepatic encephalopathy

Preparation: Kava from Vitamin World plus an unspecified tea also containing kava in a dosage of 600 mg per day for six months

Co-medication:

- Psyllium
- Vitamins B6 and E
- St. John’s wort extract
- Phytoestrogen with Mex yam (*Ipomea batata?*), black cohosh (*Cimicifuga racemosa*) and dong quai (*Angelica sinensis*) for 4 months

As a preexisting medical condition the report states an abdominal hysterectomy. Reportedly, other etiologies of the hepatic incident were excluded, however details about how this was done are missing. According the MCA assessment, no alcohol was consumed in over 5 years.

Even though the remainder of the other reported medical products seem inconspicuous, isolated reports on hepatotoxic effects of isolated ingredients of *Ipomea batata* can be found in the literature (288).

With the information available kava might or might not have contributed to the incident. With the composition of the drugs ingested in part being unknown, the causality can at best be evaluated as “doubtful”. The EMEA rated it as “probable”.

5.5 Canadian case (EMEA identifier no. 66)

Patient: female, 53 years

Reported adverse effects: jaundice, abnormal LFTs

Preparation: not stated, duration of intake unknown

Co-medication:

- St. John’s wort
- Multivitamins

The patient recovered after stopping kava “and other herbal preparations”. As the only known concomitant herbal medication was St. John’s wort, this might imply that there were indeed other unknown medications.

The patient had a history of alcohol-induced hepatitis with an average intake of 6 beers a day. However, she stated not to have drunk since then. There is no information regarding virus serology or other examinations, also the claim of abstinence for an unknown period of time would have to be taken for granted.

The EMEA evaluated this report as “possible”. However, the available information would rather suggest a “doubtful”.

5.6 French case report (EMEA identifier no. 63)

Patient: female, 60 years

Reported adverse effects: nausea, increased γ GT

Preparation: not stated, duration of intake at least one year

Co-medication: none stated

The patient recovered after stopping kava.

There is no information regarding preexisting medical conditions, virus serology or other examinations, or

alcohol intake. Concerning the deviation of γ GT after one year of continuous and uneventful intake of kava does not seem to fit into the picture of typical hepatotoxicity, which - if immunologically triggered - would be expected to occur within the first three months of intake. For hepatotoxicity triggered by metabolic idiosyncrasy or even direct and dose dependent toxicity there is no clue in the long term experience with traditional kava use as well as the 100 years of experience with pharmaceutical extracts. The EMEA evaluated this report as "possible". However, in view of the long term application of kava the available information would rather suggest a "doubtful".

6. Causal relationship cannot be evaluated from the available information

In 30 of the reports, the background information is so scarce that an evaluation of the case is not possible. In several of these cases, it is not even clear what type of side effects actually occurred. Reports of this kind can only be used as an argument to improve the vigilance towards certain effects: if such kind of „rumors“ are presented by different and independent sources, these incidences will have to receive more attention.

6.1 BfArM-No. 92901203

Additional sources: MCA identifier no. 2; EMEA identifier no. 11
Patient: RW, male, 35 years
Date of entry: December 16, 1992
Reported adverse effects : Cholestatic hepatitis
Preparation: Neuronika (200 mg D,L-kavain), twice daily, orally for an extended duration until manifestation of adverse effects.
Co-medication: Unknown
Duration of usage: Unknown
Outcome: Recovery after treatment

Even the most basic data necessary for an evaluation is missing. The case was classified as "not assessable" by the MCA and as "possible" by the EMEA.

6.2 BfArM-No. 99003911

Additional sources: MCA identifier no. 13; EMEA identifier no. 19
Patient: MF, female, 62 years
Date of entry: April 8, 1999
Reported adverse effects: Hepatic cell damage
Preparation: Kavatino (60 mg kavalactones, ethanol extract), unknown dosage, unknown duration.
Co-medication: Unknown
Outcome: Unknown

Based on the statements by the representative of the producing company, the patient was hospitalized due to complaints related to icterus. After discontinuation of the medication (co-medication existed but was not specified), the complaints were fully reversible. There was supposedly a reexposure to Kavatino with reoccurring complaints. The clinic's physicians, however, refused to cooperate in the clarification of this incidence. Virus serology, excluding diagnostics and alcohol consumption, are unknown.

The MCA indicates a positive rechallenge with Kava and on this grounds classifies the case as "probable". However, a rechallenge cannot be deducted from the existing data. Possibly, the MCA confused the case with the report no. [99006005](#), where a positive rechallenge is claimed. The latter case was classified as "not assessable" by the MCA, and as "probable" by the EMEA.

6.3 BfArM-No. 99500453

Additional sources: MCA identifier no. 11; EMEA identifier no. 17
Patient: KL, female, 59 years
Date of entry: November 14, 1999
Reported adverse effects: Hepatic cell damage
Preparation: Limbao (120 mg kavalactones, ethanol extract), 240 mg kavalactones over 4.5 months.
Co-medication: 10 mg butylscopolaminium bromide (Buscopan), one suppository when needed,

for 15 years. No label-stated hepatic effects.

The outcome of this case was unknown when the report was issued.

According to the information by the BfArM it is questionable whether Limbao was taken at all. If Limbao was used, it was certainly taken above the dosage recommended by the monograph. Due to a lack of data, such as excluding diagnostics, clinical laboratory reports, virus serology or ethanol consumption, a true case evaluation could not be made. The case was classified as “not assessable” by the MCA, and as “possible” by the EMEA.

6.4 BfArM-No. 01003089

Additional sources: MCA identifier no. 22; EMEA identifier no. 24
Patient: AW, female, 34 years
Date of entry: May 2, 2001
Reported adverse effects: Hepatitis, elevated liver enzymes
Preparation: Kava ratiopharm (120 mg kavalactones, ethanol extract),
120 mg/day, orally over 3 months.
Co-medication: 100 µg levothyroxine + 130 mg KJ (Jodthyrox), p.o.,
dosage and duration of treatment not known.

The patient recovered.

It can be assumed that the intake of levothyroxine was a long-term use. There is no information on the differential diagnostics, virus serology and ethanol consumption. The case cannot be evaluated based on the existing data. Referring to very rare reports of hepatotoxicity connected to the intake of levothyroxine, the MCA classified the case as “possible”, as well as the EMEA.

6.5 BfArM-No. 01004110/99006200

Additional sources: MCA identifier no. 23/25 (recognized duplicate entry);
EMEA identifier no. 25/27 (unrecognized duplicate entry)
Patient: CH, female, 34 resp. 35 years
Date of entry: June 15, 2001 / August 27, 1999
Reported adverse effects: Jaundice, elevated liver enzymes, hepatitis
Preparation: Antares (120 mg kavalactones, ethanol extract), 120 mg/day, orally for 4
months
Co-medication: Paracetamol (acetaminophen) 500 mg if needed.
St. John’s wort extract (Hypericum Aar)

The patient has fully recovered on discontinuation of the treatment.

Based on the statements by the representative of the manufacturer, the patient suffered from multiple sclerosis. The physician did not communicate any additional data with regard to administration, dosage and duration of other drug treatments, except for the St. John’s wort product, which has no known liver effects. In particular, the treating physician did not provide any information in connection with the therapy of the multiple sclerosis. It can be expected that the patient was at least immunosuppressed, and therefore, the intake of other potentially hepatotoxic drugs should be considered. Due to the absence of such data, the case should be at best classified as “doubtful”. The MCA referred to the intake of acetaminophen and classified the case as “possible”. The EMEA gave a “possible” independently for both entries of the duplicate case report. According to the BfArM, the lack of other medications and the amelioration of the symptoms on discontinuation (dechallenge) point to a “probable” causal relationship of kava.

6.6 BfArM-No. 01006229, liver transplant

Additional sources: MCA identifier no. 30; EMEA identifier no. 31
Patient: HM, male, 32 years
Date of entry: August 29, 2001
Reported adverse effects: Bilirubinemia, encephalopathy, elevated liver enzymes,
hepatitis, liver necrosis, liver cell damage.
Preparation: Antares (120 mg kavalactones, ethanol extract), 240 mg/day orally
for 2-3 months
Co-medication: occasional use of valerian (Baldrian Phytion).

At the time of the case evaluation (August 4, 2001), the patient had not yet recovered. A liver transplant was finally necessary.

A virus hepatitis and an autoimmune hepatitis could be excluded.

According to the statements by the representative of the manufacturer, the company was only informed by the BfArM after a delay of over two months. Even then, the BfArM did not provide the details of the case

report which - according to the statements in the reasoning of the kava ban - the authorities claim to possess. According to the BfArM, the hospital's doctors did not confirm any other drug intake than the medication already mentioned. However, the hospital's physicians can only comment on medications known by them or proven by corresponding analyses. Thus, such a statement would not exclude the possibility that other medications were in fact taken. Until more information is available, this case should be classified as „not assessable“. The MCA classified this case as such, whereas the EMEA concluded a “probable”.

6.7 BfArM-No. 01009681

Additional sources: EMEA identifier no. 35
Patient: male, 45 years
Date of entry: November 16, 2001
Reported adverse effects: elevated liver enzymes
Preparation: Kavacur (120 mg kavalactones, ethanol extract), 120 mg/day for 3 months
Co-medication: none stated
There is no more information available for this case report.

The data is insufficient for an assessment, in accordance to the evaluation als “unassessable” by the EMEA.

6.8 BfArM-No. 01010536

Additional sources: EMEA identifier no. 37
Patient: IH, female, 45 years
Date of entry: unknown
Reported adverse effects: abdominal pains, fatigue, pathologic urine, decolored feces, increased liver enzymes, bilirubinemia, hepatitis, liver failure
Preparation: Maoni (45 mg kavalactones, ethanol extract), 45 mg/day for 4 months
Co-medication:

- artichoke extract, occasionally
- St. John's wort extract until first intake of kava

The report states no other medication in the last 4 months prior to the incident.

The patient is slightly obese. On admittance to the hospital, the patient complained about fatigue and abdominal pains, decolored feces and dark urine. The liver function parameters were abnormal: SGOT 700 U/l, SGPT 1000 U/l, LDH 400 U/l, γ GT 250 U/l, and alkaline phosphatase 360 U/l. CRP was 11 mg/l, creatinin and urea within the normal range. Total serum protein (6 g/100 ml) and prothrombin (62%) were decreased. While CRP and creatinin remained in the normal range, in the further course of the incident total bilirubin increased from initially 20 mg/100 ml to almost 30 mg/100 ml, whereas total serum protein decreased to 4.6 g/100 ml and prothrombin to almost 40%.

An alcohol abuse was excluded, the result of the serologic examination was negative. The sonographic examinations did not show any focal lesions in the liver, the liver veins were not dilated. There were signs of an ascites. The extrahepatic bile ducts were inconspicuous, and there was no sign of a hepatomegaly or a portal vessel thrombosis. A liver biopsy was not performed.

After discontinuation of the kava product and amelioration of the general health state of the patient she was dismissed from the hospital.

Assessment of the co-medication:

Artichoke products are taken for symptoms of hepatic insufficiency. They are inconspicuous in regard of triggering liver effects, in contrast artichoke leaf extract stimulates hepatic bile formation and bile flow. However, the intake of a liver active preparation does give a hint on a preexisting hepatic insufficiency, even though this cannot be proven with the available data. On the other hand, the existing data is not sufficient to prove a causal relationship of kava.

The patient herself commented her case in an internet forum. There she stated severe toxic effects on the liver and kidneys, jaundice and a loss of her hair. She claimed to have almost lost her life due to kava, and the evaluation of a law suit against the producer. However, the report from the hospital does not mention a loss of the hair or toxic effects on the kidneys.

The data is insufficient for an assessment, in accordance to the evaluation as “unassessable” by the

EMEA.

6.9 BfArM-No. 02000370

Additional sources: EMEA identifier no. 39
Patient: female, 46 years
Date of entry: 1998
Reported adverse effects: disturbed general health, liver cirrhosis
Preparation: Antares (120 mg kavalactones, ethanol extract), 240 mg/day for 3.5 months
Co-medication:

- contraceptive treatment: 2 mg ethinylestradiol valerate resp. ethinylestradiol valerate + 0.15 mg levonorgestrel (Klimonorm)
- Cyclandelate (Natil) 400 mg per day

The patient was hospitalized with clinical symptoms of a beginning liver cirrhosis. A viral infection was excluded, as well as an autoimmune hepatitis. After discontinuation of all medications the general state of the patient slowly ameliorated. There is no more data available.

According to the producer the patient was professionally exposed to mercury. The time frame of 3.5 months of kava intake is too short as to give an adequate explanation for the evolution of the liver cirrhosis.

Assessment of the co-medication:

The liver effects of contraceptives are discussed in section [9.2](#).

For cyclandelate, no hepatic adverse effects are labeled.

A causality of the adverse effect by other factors than kava seems possible, but not assessable with the available information. The BfArM evaluated the case as “probable” for kava, as the authorities did not accept the former mercury contacts for granted, and did not rate the potential hepatotoxicity of the contraceptive treatment as high enough for triggering the observed effects. The EMEA evaluated the case as “unassessable”.

6.10 BfArM-No. 02002541

Patient: female, 52 years
Date of entry: July 13, 2001
Reported adverse effects: diarrhea, elevated liver enzymes
Preparation: Kava ratiopharm (60 mg kavalactones, ethanol extract),
60 mg per day over 3.5 months
Co-medication: none stated

There is no additional information for this case except for the elevated transaminase values. The available data is insufficient for an evaluation.

6.11 BfArM-No. 02002732

Additional sources: EMEA identifier no. 44
Patient: female, 24 years
Date of entry: January 2, 2002
Reported adverse effects: impaired general health status, painful abdomen, dry mouth,
bilirubinemia, elevated liver enzymes, jaundice
Preparation: Maoni forte (120 mg kavalactones, ethanol extract), 120 mg per day over 3
months
Co-medication: none stated

There is no additional information for this case. The available data is insufficient for an evaluation. The case was evaluated as “unassessable” by the EMEA.

6.12 BfArM no. 01006939

Additional sources: EMEA identifier no. 33
Patient: male, 36 years
Date of entry: August 1, 2000
Reported adverse effects: Acute necrotic hepatitis
Preparation: Laitan 100 (70 mg kavalactones/day) over 6 weeks
Co-medication: none stated

The patient recovered on conservative treatment. He had no known previous liver history. A viral origin or

an autoimmune hepatitis could be excluded.

The BfArM evaluated this case as a probable causality to kava. The available data is scarce and does not allow an assessment.

In view of the fact that the case was already known to the BfArM in August 2000, the report might well have been discussed with the remainder of the linelisting when the drug safety protocol was started in November 2001. The existence of this case report became known only after the ban of kava products was set in force. However, if kava is dangerous enough to justify a ban, it would have been mandatory to inform the producers and the experts in phytotherapy in time. The fact that this case was not communicated casts some doubts on the whole procedure, especially on the way how the information relayed was obviously selected. The case was rated as “unassessable” by the EMEA.

6.13 BfArM-No. 02003278

Additional sources: EMEA identifier no. 47
Patient: male, 50 years
Date of entry: June 21, 2002
Reported adverse effects: elevated liver enzymes
Preparation: Laitan (70 mg kavalactones, acetone extract), 140 mg per day over 3 months
Co-medication: none stated

There is no additional information for this case. The available data is insufficient for an evaluation and was rated as “unassessable” by the EMEA.

6.14 BfArM-No. 02003559

Additional sources: EMEA identifier no. 48
Patient: male, 50 years
Date of entry: January 12, 2002
Reported adverse effects: jaundice
Preparation: Kava ratiopharm (60 mg kavalactones, ethanol extract), 120 mg per day over 6 months
Co-medication: none stated

There is no additional information for this case. The available data is insufficient for an evaluation and was rated as “unassessable” by the EMEA.

6.15 BfArM-No. 02004364

Additional sources: EMEA identifier no. 49
Patient: female, 32 years
Date of entry: March 10, 2002
Reported adverse effects: hepatitis, elevated liver enzymes
Preparation: Kavacur (120 mg kavalactones, ethanol extract), 240 mg per day over 4 weeks
Co-medication:

- Contraceptive with 0,15 mg desogestrel and 0,03 mg of ethinylestradiol (Marvelon) for an unknown period of time.

The hepatotoxic potential of contraceptives is discussed in section [9.2](#).

There is no additional information for this case. The available data is insufficient for an evaluation and was rated as “unassessable” by the EMEA.

6.16 BfArM-No. 02005178

Patient: female, age unknown
Date of entry: July 2001
Reported adverse effects: liver cell damage, liver failure
Preparation: Laitan (70 mg kavalactones, acetone extract), 70 mg per day over 2 months
Co-medication: none stated

There is no additional information for this case. The available data is insufficient for an evaluation.

6.17 BfArM-No. 02001414

Additional sources: EMEA identifier no. 41
Patient: female, 46 years
Date of entry: November 25, 2001
Adverse effects reported: elevated liver enzymes, jaundice

Preparation: Antares (120 mg kavalactones, ethanol extract), 360 mg/day orally for 28 days
Co-medication: none stated

By serology, a virus hepatitis A, B and C as well as EBV be excluded. The serology for CMV was unclear, a cytomegaly virus infection could not be excluded. Reportedly, there was no indication of other possible causes. The liver function returned to normal on discontinuation of the kava product.

It can be speculated if the information yielded in the line listing is really complete. The BfArM assessed the case as a “probable” causality. According to the producer the report was not assessed by a specialist for liver diseases, and was badly documented. Even though the dosage ingested was three times that recommended by the producer and by the German monograph, the available data does not allow an assessment. Consequently, the case was rated as “unassessable” by the EMEA.

6.18 Weekly magazine report (liver transplant)

This case was reported by the weekly magazine “Stern” as an example of the inherent dangers of phytotherapy (117). There is no corresponding case report in the line listings of the authorities, even though the regulations are to report severe adverse events without delay. As the case reportedly was observed in winter 2001, it should have appeared in the line listing dated June 24, 2002.

Patient: female, 60 years
Date of entry: no entry in official line listings, media report
Reported adverse effects: liver failure with subsequent liver transplant
Preparation: note stated, “recommended dosage” for 3 months
Co-medication: none stated

There is no additional information for this case. The available data is insufficient for an evaluation.

6.19 FDA case no. 11444 (fatal outcome)

Patient: male, 24 years
Date of entry: August 30, 1996
Reported adverse effects: hepatic encephalopathia, fulminant hepatic failure, death
Preparation: Cybergenics product suite “Hard gainers”. Kava is listed as an ingredient in Hard Gainers 6 as one of 6 herbs, total 200 mg. Supposedly taken 3-4 weeks prior to hospitalization

Co-medication:

- Cybergenics “Mega weight gain”
- Vanadyl sulphate
- Multivitamin preparation
- Vitamin C
- Chromium piccolinate

There is no additional information for this case. The products taken are used for rapid muscle mass gain and body fat reduction. In body builder circles the use of anabolic steroidal preparations or other medical “quick starters” is not unusual, some of these products are well known for their potential adverse hepatic effects (289). However, the available data is insufficient for a concise evaluation.

6.20 FDA case no. 14951

Additional sources: EMEA identifier no. 59
Patient: female, 51 years
Date of entry: May 1st, 2001
Reported adverse effects: elevated liver enzymes to 150% of normal
Preparation: not given. Duration of intake: 4 months
Co-medication:

- Vitamin D
- Fish oil
- Multivitamin/mineral supplement
- Omega-3-product
- Gingko biloba extract

In addition of the elevated liver enzymes (AST and ALT 1.5 times normal) the patient had complained about foot cramps. Reportedly the symptoms vanished on discontinuation of the kava product. There is no additional information for this case, especially regarding the liver symptoms. Even though high doses of omega-3 fatty acids can produce transient elevations of the liver enzymes as a non pathologic reaction pattern, the available information does not allow an evaluation of the case. By the EMEA the causality of kava was however evaluated as “probable”.

6.21 FDA case no. 14995

Additional sources: EMEA identifier no. 60
 Patient: female, 37 years
 Date of entry: July 16, 2001
 Reported adverse effects: jaundice, fatty infiltration of the liver
 Preparation: “Kava gold”, 500 mg kava extract per tablet, corresponding to 150 mg kavalactones per tablet. Five tablets per day corresponding to 750 mg kavalactones for 3-4 weeks.

Co-medication:

- Homeopathic preparation (Dercut) against erythema containing *Cistus canadensis* D3 12.5%, *Hydrocotyle* D4 14%, *Mezereum* spag. D3 14.5%, *Ranunculus bulbosus* D4 15%, *Sarsaparilla* D2 14%, *Fumaria officinalis* spag. extract 14%, *Ledum palustre* extract 2%, *Viola tricolor* spag. extract 14%
- Homeopathic preparation (Septonsil) against respiratory inflammations containing *Ailandus glandulosa* D3 14%, *Barium carbonicum* D8 14%, *Belladonna* spag. D4 14%, *Lachesis* D8 14%, *Phytolacca americana* D4 14%, *Clematis recta* extract 10%, *Echinacea angustifolia* spag. extract 10%, *Teucrium scorodonia* spag. extract 10%
- various non defined vitamin, mineral and herbal supplements
- bovine colostrum
- undefined four products “suite” for six weeks until one week prior to the incident

As an underlying medicinal condition, underweight was stated.

There is no additional information available for this case. The “homeopathic” preparations on closer inspection reveal themselves as a mixture of real homeopathic dilutions, spagyric ingredients and plant extracts, which makes an assessment practically impossible. Both preparations are prescribed for defined indications, thus one can assume that there was more to the preexisting medical condition of the patient than stated. With the undefined product suite and thus unknown further constituents taken by the patient, the causality of kava in this case is unassessable, in spite of the gross overdose of kava. By the EMEA the causality of kava was however evaluated as “possible”.

6.22 FDA case no. 15249

Patient: male, 53 years
 Date of entry: January 2, 2002
 Reported adverse effects: pain in liver area
 Preparation: Nature Pharma Kava. 2 capsules each on two occasions, once March 15, 2001, second time unknown

Co-medication: none stated

The case was based on a self report. As a preexisting medical condition, the patient indicated some allergies.

There is no additional information for this case, especially regarding the liver symptoms. Without further information it is questionable if there was an adverse liver effect at all, as the intake of kava occasionally causes unspecific gastrointestinal complaints. The case has to be evaluated as “not assessable”.

6.23 FDA case no. 15250

Additional sources: EMEA identifier no. 54
 Patient: male, age unknown

Date of entry: January 2, 2002
Reported adverse effects: high liver enzymes, fatty liver
Preparation: NutriZAC, 50 mg of kava extract as one ingredient with 15 mg of kavalactones per unit, taken over 2 years in a dose of 30 mg kavalactones per day.

Co-medication: multivitamin supplement

The case was filed as a self report. As a preexisting medical condition, the patient indicated some environmental allergies, allergy related asthma and overweight. According to the self-estimate a moderate alcohol consume was stated.

There is no additional information for this case, especially regarding the selfdiagnosis of the liver symptoms. Also no information on the personal assessment of the moderate alcohol consume, possible other medications and further examinations are available. The case has to be evaluated as “not assessable”. The EMEA evaluated it as “probable”.

6.24 FDA case no. 15252

Additional sources: EMEA identifier no. 61

Patient: female, age unknown

Date of entry: January 1, 2002

Reported adverse effects: fatigue, nausea, vomiting, extremely elevated LFTs

Preparation: TruNature Kava with 250 mg kava extract per capsule, standardized to 75 mg kavalactones. Intake of 1-3 capsules (150-225 mg kavalactones) per day for approximately 3 months.

Co-medication:

- Dextrim green tea formula with calcium (23 mg), chromium dinicotinate glycinate 83 µg, bitter orange peel powder extract 120 mg, 340 mg of a blend of Siberian ginseng, green tea with added caffeine, fenugreek seed extract, guarana seed extract with added caffeine, kola nut extract with added caffeine, ginger root, liquorice root and vanadium amino acid chelate, intake for 2 weeks during the three month use of Kava
- Coenzyme Q10
- “Snorease” with bitter orange extract, Coenzyme Q10 and bromelain.

The case was filed as a self report. As a preexisting medical condition, the patient indicated allergies against sulfa drugs.

There is no additional information for this case, especially regarding the selfdiagnosis of the liver symptoms. Also no information on alcohol consume, possible other medications and further examinations are available. The case has to be evaluated as “not assessable”. The EMEA evaluated it as “probable”.

6.25 FDA case no. 15267

Additional sources: EMEA identifier no. 62

Patient: female, 51 years

Date of entry: December 28, 2001

Reported adverse effects: increased liver enzymes

Preparation: not given, intake for approximately 2 months.

Co-medication:

- Gingko biloba extract
- Ginseng extract
- St. John's wort extract
- MSM
- Vitamins A, D and E
- Calcium/Magnesium complex

No preexisting medical condition was stated. The liver enzymes returned to normal upon discontinuation of kava, MSM and gingko.

There is no additional information for this case, especially on alcohol consume, possible other medications and further examinations. Although the intake of vitamin A can cause hepatotoxic effects, especially when overdosed (287), the case has to be evaluated as “not assessable” based on the available data. The EMEA evaluated it as “possible”, based on a supposed positive rechallenge and a negative screening for hepatitis A-C. The the reported rechallenge the EMEA states that there were no details provided. In contrast,the

original US American line listing of the FDA does not state a rechallenge or a virus serology.

6.26 FDA case no. 15320

Patient: female, 41 years
Date of entry: September 16, 1999
Reported adverse effects: acute liver failure
Preparation: Limbao (ethanolic kava extract, standardized to 120 mg kavalactones per capsule),
dosage unknown, duration of intake unknown
Co-medication:

- Loratadine (Lisino) 10 mg/day 3 months prior to the incident (February 18 to February 24, 1999)
- St. John's wort powder from January 21, 1999 to May 9, 1999 (date of incident)
- Contraceptive with ethinyl estradiol
- infusion with NaCl 0,9%

No preexisting medical condition was stated. The incident reportedly occurred on May 9, 1999. No explication was given for the stated infusion of sodium chloride.

Assessment of the comedication:

A quick scan of the medicinal literature yielded two case reports on adverse hepatic events under loratadin ([290](#); [291](#)). However, the intake occurred only for 6 days, three months prior to the incident.

There is no additional information available for this case, especially on alcohol consume, possible other medications and further examinations. The case has to be evaluated as "not assessable".

6.27 Canadian case report (EMEA identifier no. 67)

Patient: male, 38 years
Reported adverse effects: increased transaminases, hepatitis
Preparation: Kava kava liquid extract with 30% kava root, standardized to 5% kavalactones, 2 times 12 gtt corresponding to approx. 50 mg kavalactones per day for 2 weeks
Co-medication: none stated

No preexisting medical condition was stated. Reportedly, the patient does not drink alcohol.

No additional data related to virus serology, professional or environmental hazards or further examinations are available. Based on the existing information, the case has to be evaluated as "not assessable". The EMEA evaluated it as "probable".

6.28 Canadian case report (EMEA identifier no. 65)

Patient: female, age unknown
Reported adverse effects: abnormal hepatic function
Preparation: not stated, long term application
Co-medication: none stated

The outcome of this case report is unknown.

As no additional data is available, the case was evaluated as "unassessable" by the EMEA.

6.29 French case report (EMEA identifier no. 64)

Patient: female, 39 years
Reported adverse effects: increased transaminases
Preparation: not stated, duration of intake 2 months
Co-medication: not stated, but reportedly may cause hepatotoxicity

The patient recovered after stopping kava. There is no indication concerning the nature of the concomitant medication taken, and it is not known if these drugs were also stopped in the incidence.

The EMEA evaluated this report as "possible". However, in view of the suspected intake of other drugs with known hepatotoxic potential the available information would at best suggest a "doubtful", and more likely a "not assessable".

6.30 Australian TGA case report (fatal outcome)

Patient: female, age unknown

Reported adverse effects: liver failure

Preparation: herbal combination of three extracts, with kava as one ingredient,
dosage unknown, duration of intake 4 months

Co-medication: reportedly several complementary medicines

The patient died in the course of the liver failure. The kava extract was thought to be the most likely causative agent in the incident.

Neither the concomitantly taken medication nor the composition of the herbal product is known. There is no further data concerning the course of the liver failure. With the meager background data on this case report, the case has to be evaluated as “not assessable”.

7. Causal relationship probable at monograph-conform dosage

From the original 76 suspected cases, there are only four cases where a causal relationship to kava intake is probable. Of these four cases, only one is related to a monograph-conform dosage regimen ([2](#)), whereas in another one, the dosage scheme is not known ([3](#)). The remaining two case reports are associated with overdosage according to the standards of the German monograph ([4](#)). In one of the case reports associated with recommended use and a high probability of causal relationship to kava intake, an immunological idiosyncratic hepatic reaction type combined with a cytochrom P450-2D6 deficiency was stated. A comparable mechanism was also found in one of the case reports associated with overdosage (IKS-Nr. [2000-0014](#); see below).

In principle, immunological drug sensitization can never be excluded for any agent. In both case reports where such a hypersensitization was reported, the hepatic complications were related to enzyme defects of the hepatic metabolism. If this kind of mechanism should be representative for hepatic adverse events from kava, such effects would occur only very rarely, due to the very low probability of the combination of a poor metabolism and sensitization to kava-metabolites.

7.1 Literature case: *Strahl et al. (1998)*

The case described by Strahl et al. (1998) ([2](#)) was the first relatively well-documented case of a serious hepatic adverse event related to kava. The evaluation of the incidence was complicated by the fact that the kava preparation could not be identified with certainty. Based on the information by the authors, an ethanol extract with 60 mg kavalactones per unit was used. Communication with the German producers revealed that none of the companies had received any information about this case. Obviously, the authors did not file the obligatory report to the authorities. However, doubts regarding the intake of a kava product were, in this case, unfounded. With further details of the same case provided by third parties, a causal relationship to kava intake is probable ([69;70](#)).

Additional sources: MCA identifier no. 10; EMEA identifier no. 4

Patient: female, 39 years

Date of entry: Unknown

Reported adverse effects: Acute necrotic hepatitis

Preparation: Unknown, 60 mg kavalactones/day over 6 months

Co-medication:

- Paroxetine, 20 mg/day
- Occasional use of St. John's wort.
- Contraceptive (0.15 mg desogestrel + 0.02 mg ethinylestradiol) for 6 years.

The patient was admitted to the hospital in order to investigate the elevated transaminases, bilirubin and lactate dehydrogenase. The hepatitis serology was negative; the sonography results were inconspicuous. The histological image was consistent with a diffuse and necrotizing hepatitis, suggesting a viral or toxic genesis. After discontinuation of the medications, the liver values continued to rise for a week and then returned to normal.

Six months later, a new increase of transaminases could be observed. A renewed kava intake was stated, this time without further co-medication. The clinical image hinted to a drug induced toxic hepatitis. Serology allowed the exclusion of hepatitis A, B and C, CMV, EBV, toxoplasmosis and leptospirosis. The sonographic image revealed a former hepatitis episode. The histopathological findings were consistent with an acute, necrotizing hepatitis. An autoimmune hepatitis could not be excluded with certainty. After 4 weeks, the liver values improved, reaching normal levels after 4 months. Based on the positive rechallenge to kava, a lymphocyte transformation test was not considered as necessary. The shortened latency period, however, points towards an immunological sensitization on initial intake.

Assessment of the co-medication:

Whereas St. John's wort does not have any known adverse liver effects, for paroxetine, transient elevations of liver enzymes are labeled. In the literature, severe cases of liver toxicity reportedly caused by paroxetine can be found ([282-284](#)). Liver function impairment by contraceptive treatment is discussed in section [9.2](#). Based on the positive rechallenge and the negative virus serology, one can assume that this case has indeed a causal relationship to kava. Russmann et al. (2001) ([69](#)) suspect a relationship to a cytochrome P450-2D6 deficiency: they investigated the metabolic pattern of the patient and found a congenital deficiency for this enzyme system. The reported incidence could, therefore, have been caused by an immunological event based on the hypersensitization to a reactive kava metabolite. This explanation is supported by a positive rechallenge and the shortened latency period in the second incidence. Allergic reactions to plant derived drugs or isolated ingredients can never be excluded. Most drugs state corresponding hints in the package leaflets. Even though rare cases of allergies to kava were described as dermatological events, the nature of immunologic reactions does not allow the exclusion of a participation of other organs in an allergic reaction.

The case report was classified as "probable" by the MCA and the EMEA.

7.2 Literature case: Humbertson et al. (2001) (liver transplant)

The case report was published as an abstract in 2001 from the children's hospital of Pittsburgh, PA ([3](#)).

There is no corresponding case report in the line listing of the FDA.

Patient: female, 14 years

Date of entry: not given

Reported adverse effects: Fulminant hepatic failure with liver transplant

Preparation: unknown. Intake for 6 months in unknown dosage, discontinued for 1 month, resumed intake for unknown duration.

Co-medication: none stated

No preexisting medical condition was stated. Due to deteriorating liver function tests the patient had to be transplanted. The liver biopsy showed hepatocellular necrosis consistent with chemical hepatitis. The workup for alternative causes was negative. However, the alternatives examined are not stated. Also, the duration and dosage of kava intake is not known. According to the authors the causality of kava is supported by the circumstances. With the given details the conclusion of a causality of kava may or may not be drawn, depending on the nature of the work up and the definite exclusion of preexisting medical conditions and the intake of other drugs.

8. Causal relationship probable with overdosage of kava extract

In addition to the above mentioned case report related to monograph conform dosage (Strahl et al. [2](#)), there are two cases with a possible causality to kava, associated with non-recommended dosages.

In one case, an immunological reaction and a concurrent cytochrome-P450-2D6 deficiency could be detected (IKS-case [2000-0014](#)).

8.1 IKS-Case number 2000-0014

Additional sources: medicinal literature ([69-71](#)); MCA identifier no. 16;
EMEA identifier no. 7

Patient: female, 33 years

Date of entry: March 21, 2000

Adverse effects reported: Jaundice, cholestatic hepatitis

Preparation: Laitan (70 mg kavalactones, acetone extract), 210 mg/day orally for 2-3 months.

Co-medication:

- Pain relief: 125 mg propyphenazone + 0.5 mg dihydroergotamine-mesylate+ 40 mg caffeine (Tonopan), taken once due to alcohol intake the evening before (see below).
- Pain relief: 250 mg paracetamol (acetaminophen) + 150 mg propyphenazone + 50 mg caffeine (Saridon), taken to fight the hang-over from the day before (see below).
- Homeopathic combination product (Exepta): *Acidum silicicum* D12 + *Arnica montana* D6 + *Carbo vegetabilis* D12 + *Echinacea angustifolia* D3 + *Graphites* D6 + *Myristica sebifera* D6 + *Sulfuris iodidum* D6, start of intake: February 5, 2000, last date of intake: February 20, 2000.

Except for acetaminophen, the co-medication is inconspicuous concerning hepatotoxicity. Acetaminophen probably did not contribute to the hepatic event, as it was taken on the first day of the onset of symptoms. The patient stated a massive alcohol intake on February 12, 2000, with otherwise little alcohol consumption. The complaints started on February 13, firstly interpreted as a hang-over from alcohol, which led to the use of the pain medications listed above. Following the hangover, the patient suffered increasingly from inappetence, fatigue, epigastric pressure and severe weight loss. On February 20, she noticed a dark coloration of the urine, had orthostatic complaints and dyspnea when active. Laitan was discontinued. The patient was hospitalized on February 26, 2000. The virus serology for hepatitis A-C was negative, and there was only a weakly positive EBV-reaction which could indicate a reactivation of a previous infection. Obstruction of the bile ducts and autoimmune disease could be excluded. The transaminases were extremely elevated. The liver biopsy pointed towards a drug-induced, toxic hepatitis, and, despite the massive alcohol intake on February 12, an ethanolic genesis could be excluded. The patient had fully recovered by May 4, 2000.

After recovery, a lymphocyte-transformation test was performed, which turned out positive for Laitan but negative for the homeopathic combination product. Subsequently, a cytochrome P450-2D6 deficiency could be detected in the patient. Considering the positive outcome of the lymphocyte transformation test, Russmann et al. (2001) ([69;70](#)) point towards an idiosyncratic-immunologic hepatitis, as in the case published by Strahl et al. (1998) ([2](#)).

The Swiss IKS evaluated this case as „probable“, and with the conclusive documentation this evaluation should be accepted. The MCA and the EMEA, too, classified the case as “probable”.

8.2 IKS-Case number 2000-3502, Liver transplant

The case was reported by a hospital.

Additional sources: medicinal literature (70-72); MCA identifier no. 18;
EMEA identifier no. 9

Patient: male, 50 years

Date of entry: Unknown

Reported adverse effects: Acute subfulminant hepatitis with liver transplant

Preparation: Laitan (70 mg kavalactones, acetone extract), 210-280 mg kavalactones for 1.5 months

Co-medication:

- Paracetamol (acetaminophen) 500-1000 mg, shortly before transplant (not related to the evolution of this case; see below).
- Occasional intake of evening primrose oil, but not in October and November 1999.
- Yeast preparation.

No hepatotoxic effects are known for evening primrose oil and yeast preparations.

Kava was taken from the end of October to December 7, 1999. End of November, the patient noticed a

dark coloration of the skin, similar to a sun tan. On December 5, an icteric condition developed. The liver values, determined on December 7, were extremely elevated. Subsequently, the kava preparation was discontinued.

The virus serology for hepatitis A,B,C and E was negative, as well as HIV and CMV. The serology indicated signs of a previous EBV infection. The clinical symptoms, however, were not consistent with a EBV reactivation. An obstruction of the bile ducts could be excluded based on the sonographic examination. Escher et al. (2001) excluded an ethanol genesis in this case (72).

In the course of the hepatitis, an ascites and clinical symptoms of hepatic encephalopathy occurred; the patient was intubated on December 13, 1999. A liver transplant was considered. Even before the liver transplant was made, the patient developed fever, a skin rash and serious symptoms of liver failure. The patient received 500-1000 mg paracetamol (acetaminophen) for fever reduction. The liver transplant was performed on December 16, 1999. The biopsy results showed distinct signs of toxic-necrotic hepatitis. After surgery, the subsequent toxicological blood tests indicated residual levels of paracetamol (acetaminophen) corresponding to the last dosage, as well as traces of lidocain, caffeine, atracurium and metoclopramide in the urine. The detection of caffeine is possibly related to the hospital breakfast and the detection of lidocaine (local anesthetic) and atracurium (muscle relaxant used for intubations) is most likely a result of the medication related to the intubation procedure. Presumably, this is also the case with metoclopramide, a motility-lowering drug.

The IKS evaluated a causal relationship to kava as „probable“, as well as the MCA and the EMEA. The Swiss evaluation was based on an erroneous information. It refers, in addition to the Strahl publication (2), to six kava side effect cases supposedly listed by the WHO, which led to the impression of a regularly occurring adverse event. In reality, there were only three cases at the time of evaluation, but the searched keywords „hepatitis“, „cholestatic hepatitis“, „liver cell damage“ and „jaundice“ resulted in six hits from the database, which is easily explained by overlapping symptom reports in the three corresponding cases. The relevant WHO-cases correspond to the BfArM cases [93015209](#), [94006568](#) and [94901308](#). While for case no. [94006568](#) the causality to kava is very questionable, in the other two case reports a causal relationship to co-medication (diazepam and terfenadine, respectively) is an alternative explanation of the event.

Thus, at the time of the evaluation only the publication by Strahl et al. (1998) (2) would have supported the evaluation. However, the causality to kava in this case is possible, keeping in mind that the dosage exceeded the recommended range.

9. Hepatotoxic potential of frequently used concomitant medications

For reasons of simplicity, several repeatedly occurring medications were analyzed with more detail in the following sections.

9.1 Benzodiazepines

The first benzodiazepine to be introduced in the market was chlordiazepoxide in 1960 (292). The 42 years of experience with benzodiazepines revised in reviews have clearly shown that hepatic adverse events occur relatively rarely, but nevertheless exist and mostly are severe (118;293;294). Tolman (1977) counts diazepam under the drugs from which unpredictable (idiosyncratic) liver adverse events are relatively common (289). Benzodiazepines are contraindicated in patients with liver function impairment. The relatively rare side effects of benzodiazepines might cause the physicians to underestimate the inherent dangers. Most of the benzodiazepine side effects are of the idiosyncratic type and thus hard to predict. For diazepam incidence ratios were published that lead to the expectation of one hepatic adverse event in 472.000 daily doses (74). Schulze et al. (74) calculated an incidence of 0.90 cases of hepatic adverse effects in one million of daily doses for bromazepam, 1.23 cases for oxazepam, and 2.12 cases for diazepam.

Already in 1961 the first reports of hepatic side effects with chlordiazepoxide were published (292;295;296), including a case with fatal outcome (297). Whereas in most of the early case reports other drugs were involved (295;297-300) - some of which were taken out of the causality evaluation at the time of the evaluation for lack of known hepatotoxicity - some reports leave little doubt that chlordiazepoxide was the causal agent for the incident (292;301;302).

Apparently the first case report for **diazepam** dates back to 1965, when Cook et al. reported two drug-related cases of increased liver enzymes, one after chlordiazepoxide, one after diazepam (298). More case reports followed (303-305). According to Stacher (1973) liver reactions from diazepam are typically characterized as intrahepatic cholestasis with an increase of serum bilirubin and alkaline phosphatase, whereas the transaminases were within the normal range (306). This observation was based on the data from 13 patients examined. The liver parameters returned to normal within four weeks after discontinuation. Again, most patients received concomitant treatments which by today's knowledge would at least be regarded as suspicious. E.g., in one case penicillin was taken, However, in one case the penicillin therapy was already terminated when the cholestasis started, and in another case the liver values returned to normal on discontinuation of diazepam, whereas the penicillin intake was continued.

The observation of some cases of bilirubinemia under diazepam treatment was confirmed in a 28 day placebocontrolled double blind study in 46 patients receiving either diazepam, alprazolam or placebo (307). Whereas one patient receiving diazepam displayed a slight elevation of bilirubin, in one of the alprazolam-patients also an increase of SGOT was found. This latter patient however was suspected of a protocol breach by alcohol consume during the study.

Liver function impairment through diazepam was also backed by the observations of Rosanelli (1979) (308) and McIntosh (199) (309), who found a higher incidence of bilirubinemia and icterus in newborn infants, when the mother had taken diazepam ante partum.

Reports on hepatic adverse events (including fatal outcomes) can also be found for other benzodiazepines, such as **flurazepam** (310;311), **potassium-clorazapate** (312), **alprazolam** (307;313-315) or **triazolam** (316).

The safety profile of alprazolam was examined in a multicenter, placebocontrolled study (317). In 10 out of 263 patients under alprazolam medication potentially severe adverse effects were observed, among them three cases of acute toxicity, two cases of hepatitis, two cases of mania, one case of amnesia, one case of aggressive behavior and one case of depression. One of the two hepatitis patients had developed jaundice and hepatomegalia after a four week intake of 8 mg of alprazolam per day. Four days after discontinuation the liver functions test were in the normal range. The second patient had increased liver function tests after 8 weeks of 4 mg alprazolam per day, which returned to normal on cutting down the dosage of alprazolam by 50 percent. In both cases, viral causes could be excluded.

Latency until the onset of the reaction

Reynolds et al. reported the case of a 44 year old woman who developed a liver dysfunction after four months of 30 mg flurazepam per day. There were no other medications involved, and the symptoms vanished five days after discontinuation of the medication (311).

Rechallenge

Cases of liver side effects for diazepam confirmed by rechallenge can be found in the medical textbook literature (318). The evolution of an intrahepatic cholestasis on intake of chlordiazepoxide can lead to a renewed occurrence of the symptoms, but not necessarily so (300). Tedesco et al (1982) reported a hepatitis from diazepam confirmed by rechallenge (319). According to his evaluation, hepatic adverse events rarely occur under diazepam. However, due to the large numbers of prescriptions the treating physician should be vigilant towards the evolution of the patient's liver functions tests.

Hepatotoxicity of benzodiazepines in pharmacological experiments

Cholestasis and increased alkaline phosphatase as well as slight increases of SGOT and SGPT and necrotic liver cell damage on application of diazepam, oxazepam and chlordiazepoxide in dogs were already published in 1970 (320). Changes of the liver enzymes were also shown in the perfused rat liver model on application of diazepam (321). Finally, experiments with cats yielded solid hints on a potential idiosyncratic hepatotoxicity of diazepam (294;322;323), ranging up to fulminant and fatal liver necrosis. Finally, Chatterjee et al. (1997) by microscopic examination of liver tissue of diazepam-treated rats found changes in the liver parenchyma as well as a diminution of trace elements in the tissue (294;324).

9.2 Contraceptive estrogen/progesterone combinations

Icteric and anicteric hepatitis are generally labeled as potential side effects for estrogen-progesterone combinations. The occasionally observed icteric complaints seem to be connected to the estrogen component rather than to the progesterone component. Specifically for medroxyprogesterone acetate the risk of hepatic side effects seems rather limited. On the contrary, there are results from clinical and pharmacological experiments that medroxyprogesterone acetate might actually counteract the histological picture of a fatty liver or a cirrhosis (217-222). In the scope of a one year case control study in 357 patients occasional increases of bilirubin and a drop of the alkaline phosphatase were found, without affecting the transaminases (222).

However, for the estrogen component case reports of hepatic adverse events can be found in the medicinal literature (189;222;325-350). Cholestasis by oral contraceptives was counted among the relatively common unpredictable liver adverse events as early as 1977 (289). E.g., Eisalo et al. (1964) (331) reported liver function impairment after as little as 28 days of application of progesterone/estrogen components in postmenopausal women. In all cases transaminases were clearly elevated after 20 days of treatment. The effect was contributed to the estrogen component, not to the progesterone compound. Larsson-Crohn & Stenram (1965) reported two cases of jaundice in relation to the intake of contraceptives (334). Optical microscopy revealed intrahepatic cholestasis and slight hepatocellular damage. In both cases the liver symptoms appeared within the first month of intake. Stoll et al. (1965) observed

elevated transaminases and in two cases also jaundice in four postmenopausal women who obtained highly dosed hormonal combinations for the treatment of breast cancer (340). It is generally agreed that steroid jaundice is not due to hypersensitivity reactions (334). This however means that a long term intake without hepatic complications does not signify safety from estrogen jaundice, especially with highly dosed regimens. E.g., Perez-Meraz and Shields reported a case of jaundice and cholestasis from the intake of norethindrone after more than one year of consecutive intake (337). Although rare in relation to the numbers of contraceptive prescriptions, estrogen jaundice might well have contributed to some of the cases discussed for kava.

9.3 Heart burn treatment: Omeprazol/Pantoprazol/Rabeprazol

In the medicinal literature cases of adverse drug reactions of omeprazole on liver function can be found (226-228;235;351;352). For the structurally related and relatively new compound rabeprazol a case of fulminant liver failure in connection to the antimycotic compound terbinafine was published (236), whereas at least one case report states a liver failure 48 hours after the ingestion of 40 mg of pantoprazole (157).

The discussion of the mechanism of the liver reactions is still ongoing. There is a wide range of observed reactions, such as mild increases of liver values within the normal range (225;353), reversible increases of transaminases without a clinical symptoms (227;228), or fulminant liver failure (351) and hepatic encephalopathy (352). Garcia Rodriguez et al. (1997) calculated an incidence of 2.1 hepatic events in 100.000 applications (75). Under omeprazole therapy, elevated transaminases often return to normal values without discontinuation of the therapy (225).

A general intrinsic-toxic potential of omeprazole was not seen in animal experiments and clinical studies (227). In the case of a fulminant liver failure published by Jochem et al. (1992), an idiosyncratic-metabolic reaction type at a subsystem of the cytochrome P450 oxidase was the most plausible explanation (351). Due to the four week latency in the case report of Koury et al. (227) the same mechanism might have been involved there. An idiosyncratic-metabolic mechanism of hepatotoxicity was also discussed for the structurally related pantoprazole (157). In the evolution of the hepatic adverse event possibly a cytochrome P450 2C19 metabolite is involved, a hepatic metabolizing system missing in a certain percentage of the caucasian population of Europe, which might contribute to the accumulation of a potentially toxic metabolite.

Navarro et al. (1997) reported cases of omeprazole-induced hepatitis with reexposition (226). Both reactions occurred within 7-9 days after the first ingestion of omeprazole, in both cases the elevated transaminases returned to normal within four weeks.

9.4 NSAID hepatitis: Diclofenac

In the medical literature, a multitude of cases of sometimes quite dramatic liver reactions under the

application of diclofenac can be found, among these numerous cases of transient increases of liver enzyme activity, which make transient liver reactions a typical pattern of side effects under diclofenac (76;77;80;354-382). The possible influence of diclofenac on liver function has been known since 1978 (359). The analysis of clinical studies as well as of spontaneous reports of undesired effects in Great Britain yielded 29 cases of hepatic side effects among 2.56 million of patient months in the time 1979-1982. In addition, in clinical studies from the United States 19 further cases of increases of transaminases among 1227 treated patients were found, cases which were especially characterized by an increase of SGOT values. In 5 of these cases, the causality of diclofenac was evaluated as improbable, in 12 cases (0.98%) as probable, and for two patients (0.16%) as secured. In all cases, the increase of transaminases was reversible. From the clinical studies, the incidence of hepatitis was calculated as 0.26% (data base: 1773 patients) on long term treatment (383).

Incidence of hepatic adverse effects from diclofenac

The incidence of severe liver function disorders caused by diclofenac is supposed to be 2% (361;364), whereas non-severe elevations of transaminase values can be expected to occur in 15% of the patients taking diclofenac (80;357;368). The relative risk of hepatic events is increased by the factor of 8.6 for patients concomitantly treated with a potentially hepatotoxic medication, and by the factor of 10.9 if the patient suffers from a rheumatoid arthritis (77). The incidence of acute hepatic adverse events is by calculation 3.6 cases in 100.000 patients (77). Autoimmune disorders are supposed to be a risk factor for hepatic adverse events under diclofenac treatment. However, the fact that exactly this patient group will especially profit from a treatment with nonsteroidal antirheumatics might give way to a bias in the evaluation of the different risk factors (368).

For Australia in the years between 1983 and 1989, Sallie et al. (1990) estimated the number of diclofenac prescriptions to over 8 million patients, whereas the suspected cases of hepatic adverse events lead to an estimation of 3-10 cases in one million prescriptions (375;376). The pharmacovigilance system in Australia is based on a deliberate support by the physicians. Thus, Sallie et al. suppose a large number of unknown or unreported cases of increased transaminase activity by diclofenac (375;376).

Mechanism of action 1: Hypersensitivity reactions

O'Brian further specifies the hepatic adverse events by diclofenac in very rare cases of hepatitis (the causality of the hepatitis in most cases not being defined beyond doubt), and cases of transaminitis, which are quite common for nonsteroidal antirheumatics (78). The very rare hepatitis is in most cases due to a hypersensitivity reaction, and usually occurs within 2 to 12 weeks after starting the medication. Normally, the hypersensitivity reaction is not limited to the liver, but also leads to reactions in other organs. In one third of the cases affections of the skin, the lungs, kidneys and the blood forming system could be observed (78). A mechanism of the hypersensitivity type must lead to a rapid and severe reoccurrence of the symptoms on rechallenge (see below).

Mechanism of action 2: non-specific transaminitis

Non-specific increases of transaminase activity are a typical reaction of nonsteroidal antirheumatic drugs. The notion "transaminitis" means a mild form of hepatitis, with only minor histologic changes in the liver as seen by biopsies. In most cases, the transaminitis reaction is supposed to be a nuisance, rather more so because the anti-inflammatory treatment has to be suspended than just because they are estimated a severe adverse event (78). Such reactions seem to occur more frequently with diclofenac than with other nonsteroidal antirheumatics. For diclofenac an incidence of 2 to 4 % was calculated from clinical studies, most of these reactions occurred without further symptoms (76).

In their publication, Purcell et al. (1991) reported 26 cases of hepatitis by diclofenac, occurring from 6 to 417 days after starting the medication. Quite often increases of transaminase values by the factor of 30 to 40 can be seen. After suspending the medication a quick normalization of serum aspartate and alanine transaminase was observed, the values being reduced by 50% within 13 days (76). It can be assumed that in most of the cases not hypersensitisation but a metabolic mechanism was involved, which is supported by

the long duration of undisturbed intake prior to the increase of transaminase values. Diclofenac is quickly eliminated from the bloodstream. It can be assumed that the liver reactions are due to the accumulation of a metabolite of diclofenac (76).

Quick recovery of transaminase values in NSAR transaminitis

The quick recovery of transaminase values stated by Purcell et al. (1991) on suspension of the medication (76) seems to be typical for toxic-metabolic transaminitis. It is reflected in a number of case reports, such as given by Bhogaraju et al. (1999) (357), Deshayes et al. (1984) (360;364) and Jick et al. (1992) (367). Bhogaraju et al. reported a recovery of transaminase values starting from the second day after suspension of diclofenac, and a complete recovery after 6 weeks. Deshayes et al. and Jick et al. found a recovery of the liver values within 4 weeks, Paret Masana et al. (1986) even observed the recovery to a normalization of the liver values within two weeks only (373). They could rule out an immunologic mechanism, so a typical transaminitis would be the obvious cause for the adverse event. Symptoms of a hepatopathy caused by diclofenac usually occur within the first three months of treatment, usually with a fast recovery after suspension of the medication (361). Other authors state latencies between one week and 11 months (372). Diclofenac-induced hepatitis may occur totally without symptoms. Hepatocellular damage might thus occur much more frequently than expected (361).

Rechallenge

In some cases the occurrence of liver symptoms and the suspension of the medication was followed by a reexposure to diclofenac after recovery. Obviously only the cases are known where the rechallenge led to a renewed occurrence of liver symptoms.

In a case reported by Helfgott et al. (1990) the renewed liver reactions occurred after a six week treatment of diclofenac (77;365). Babany et al (1983) reported a similar case, with the adverse event reoccurring after five weeks of renewed treatment (356). A probable case of repeated reexposure was reported by Hackstein et al. (1998). Again, the latency between renewed intake of diclofenac and the reoccurrence of liver symptoms was several weeks (364). Lascar et al. (1984) described a fatal outcome of a fulminant diclofenac hepatitis after three weeks of reexposure (369).

With these latencies a hypersensitivity reaction can definitively be ruled out. In comparable cases reported by Greaves et al. (2001) and Paret Masana et al. (1986) there were only 48 hours between rechallenge and renewed liver symptoms, the cases being identified as due to a idiosyncratic hypersensitivity reaction (77;363;373).

Caution and a regular control of liver values is recommended by Bhogaraju et al. (1999) when a patient is reexposed to diclofenac after recovery of a transaminitis (357). The observation of gastrointestinal disorders might be a first warning of more severe symptoms that might follow.

Other NSAIDs

Hepatotoxicity with NSAIDs in general is a well-recognized phenomenon, e.g. with phenylbutazone ((189;384) and literature cited therein). Hepatitis is also known for other nonsteroidal drugs, such as piroprofene (229), for which reversible (after suspension) increases of transaminase values were found, which partly did not reoccur on rechallenge. A metabolic effect is more likely to be the mechanism of action than a hypersensitivity reaction (229). This kind of hepatopathy can occur even months after starting the therapy and is usually preceded by gastrointestinal disorders (229). According to Purcell et al. (1991) (76), hepatic events from non-steroidal antirheumatic drugs are declared a **class reaction** by the FDA (79).

9.5 Antirheumatic treatment: Sulfasalazine

In the medicinal literature hepatic adverse reactions to sulfasalazine are well known (247;289;385-413). Even though already in 1978 for this compound more than 100 severe incidents with liver effects were reported (389), such adverse events are generally considered as rare but severe incidents (78;403). Also known are clinically non-relevant and reversible increases of transaminases under treatment with sulfasalazine, which normally do not require an interruption of the therapy (408).

Duration until the onset of the liver reaction

Typically, hepatic sulfasalazine incidents occur three weeks after the onset of therapy, which led to the creation of the notion “three weeks sulfasalazine syndrome” (410). This kind of reaction is based on

immunologic processes, and by its immunologic nature is connected to symptoms in other organs such as skin or blood (78;410). Immunologic reactions to sulfasalazine usually occur within 14-21 days after start of the therapy. However, in one case the reaction was observed but after 15 years of continuous treatment (412). In most less severe incidents the hepatopathy was reversible upon discontinuation of sulfasalazine, however, there were also fatal outcomes under the more severe incidents (78;403).

Rechallenge

As a consequence of an idiosyncratic-immunologic mechanism, a reexposition to sulfasalazine should lead to a renewed liver reaction. Indeed such reactions were observed within 24 hours after reexposition (391;393;399). In one case report published by Caspi et al. (1992) the first liver reaction to a combination of sulfasalazine and diclofenac occurred after a longer period of otherwise uneventful medication. The second exposition to sulfasalazine happened by chance five years later, and this time the time from first intake to the liver reaction followed the typical three weeks course. The liver values returned to normal within only two weeks. Directly following this incident, a rechallenge was tried, leading to a reaction within 24 hours (388). In one case report by Losek and Werlin (1981) the hepatitis reoccurred after only 18 hours on rechallenge (402). On reexposition to sulfasalazine the liver is not always concerned. There were cases where the reexposition to sulfasalazine after a hepatic incident led to massive neurologic defects (247). However, in all cases the second reaction was decidedly more dramatic than the first event.

Transient hepatic events

Possibly the evaluation of the risk of adverse liver events by sulfasalazine is biased by the reporting of mainly severe cases. This is backed by the fact that transient hepatic effects were reported (408). Such a case was possibly presented by Miller and Broom (1983): they reported a multiple reexposition with different latency periods until the onset of the liver reaction, among others a deliberate rechallenge (412). This case report was characterized by a rapid normalization of the liver parameters after rechallenge under controlled conditions.

10. References

- (1) Kraft M, Spahn TW, Menzel J, Senninger N, Dietl K-H, Herbst H et al. Fulminantes Leberversagen nach Einnahme des pflanzlichen Antidepressivums Kava-Kava. Dtsch med Wschr 2001; 126(36):970-972.
- (2) Strahl S, Ehret V, Dahm HH, Maier KP. Nekrotisierende Hepatitis nach Einnahme pflanzlicher Heilmittel. Dtsch med Wschr 1998; 123:1410-1414.
- (3) Humbertson CL, Akhtar J, Krenzelok EP. Acute hepatitis induced by kava kava, an herbal product derived from Piper methysticum. J Toxicol 2001; 39:549.
- (4) Monographie: Piperis methystici rhizoma (Kava-Kava-Wurzelstock). Bundesanzeiger 1990;(Nr. 101 vom 1.6.1990).
- (5) Karch FE, Lasagna L. Adverse drug reactions. JAMA 1975; 234(12):1236-1241.
- (6) Schmidt M. Herbal medicinal products as the usual suspects? Reported hepatitis from Kava (Piper methysticum) intake was probably caused by diclofenac. Manuskript in Vorbereitung 2002.
- (7) Hiller K-O. Aktualisiertes Wissenschaftliches Erkenntnismaterial zu "Piperis methystici rhizoma" (Kava-Kava-Wurzelstock) ab 1995-unter Berücksichtigung relevanter früherer Studien-. Kooperation Phytopharmaka 1999;1-31.
- (8) Pittler MH, Ernst E. Efficacy of Kava extract for treating anxiety: systematic review and meta-analysis. Clin Psychopharmacol 2000; 20(1):84-89.

- (9) Pittler MH, Ernst E. The efficacy of kava extract for treating anxiety: A systematic review and meta-analysis. *Forsch Komplementärmed* 2000; 7:49-50.
- (10) Lebot V, Merlin M, Lindstrom L. Kava, the Pacific elixir. New Haven: Yale University Press, 1992.
- (11) Warnecke G. Langzeittherapie psychischer und vegetativer Dysregulationen mit Zubereitungen aus Piper methysticum. *Erfahrungsheilkunde* 1989;(6):333-338.
- (12) Warnecke G, Pfaender H, Gerster G, Gracza E. Wirksamkeit von Kawa-Kawa-Extrakt beim klimakterischen Syndrom. Eine Doppelblindstudie mit einem neuen Monopräparat. *Z Phytother* 1990; 11(3):81-86.
- (13) Kinzler E, Krömer J, Lehmann E. Wirksamkeit eines Kava-Spezial-Extraktes bei Patienten mit Angst-, Spannungs-, und Erregungszuständen nicht-psychotischer Genese. Doppelblind-Studie gegen Placebo über 4 Wochen. *Arzneimittelforsch / Drug Res* 1991; 41(6):584-588.
- (14) Warnecke G. Psychosomatische Dysfunktionen im weiblichen Klimakterium. Klinische Wirksamkeit und Verträglichkeit von Kava-Extrakt WS 1490. *Fortschr Med* 1991; 109(4):119-122.
- (15) Siegers CP, Honold E, Krall B, Meng G, Habs M. Ergebnisse der Anwendungsbeobachtung L 1090 mit Laitan Kapseln. *Ärztl Forschung* 1992; 39:7-11.
- (16) Spree MH, Croy HH. Antares - ein standardisiertes Kava-Kava-Präparat mit dem Spezialextrakt KW 1491. Therapeutische Ergebnisse und Verträglichkeit. *Der Kassenarzt* 1992;(17):44-51.
- (17) Malsch U, Kieser M. Efficacy of kava-kava in the treatment of non-psychotic anxiety, following pretreatment with benzodiazepines. *Psychopharmacol* 2001; 157:277-283.
- (18) Woelk H, Kapoula O, Lehrl S, Schröter K, Weinholz P. Behandlung von Angst-Patienten. Doppelblindstudie: Kava-Spezialextrakt WS 1490 versus Benzodiazepine. *Z Allg Med* 1993; 69(10):271-277.
- (19) Lehmann E, Kinzler E, Friedemann J. Efficacy of a special Kava extract (Piper methysticum) in patients with states of anxiety, tension and excitedness of non-mental origin - A double-blind placebo-controlled study of four weeks treatment. *Phytomedicine* 1996;(3):113-119.
- (20) Volz HP, Kieser M. Kava-kava extract WS 1490 versus placebo in anxiety disorders - a randomized placebo-controlled 25-week outpatient trial. *Pharmacopsychiatry* 1997; 30(1):1-5.
- (21) De Nicola P, Sensch KH, Scherer J. Double-blind clinical trial of a natural kavapyrone complex in elderly patients with anxiety syndromes. *Manuskript in Vorbereitung* 2002.
- (22) Scherer J. Kava-Kava extract in anxiety disorders: an outpatient observational study. *Adv Ther* 1998; 15(4):261-269.
- (23) De Leo V, La Marca A, Lanzetta D, Palazzi S, Torricelli M, Facchini C et al. Valutazione dell'associazione di estratto di Kava-Kava e terapia ormonale sostitutiva nel trattamento d'ansia in postmenopausa. *Minerva Ginecol* 2000; 52:263-267.
- (24) De Leo V, Marca AI, Morgante G, Lanzetta D, Florio P, Petraglia F. Evaluation of combining kava extract with hormone replacement therapy in the treatment of postmenopausal anxiety.

Maturitas Eur Menopause J 2001; 39:185-188.

- (25) Mittmann U, Schmidt M, Vrstyakova J. Akut-anxiolytische Wirksamkeit von Kava-Spissum-Spezialextrakt und Benzodiazepinen als Prämedikation bei chirurgischen Eingriffen - Ergebnisse einer randomisierten, referenzkontrollierten Studie. J Pharmakol Ther 2000; 9(4):99-108.
- (26) Boerner RJ. Kava Kava bei Angsterkrankungen: Wirksamkeit auf dem Prüfstand. LI 150 (Maoni forte 120 mg) bei generalisierter Angststörung: Ergebnisse einer klinischen Studie gegen Opipramol und Buspiron. Lichtwer-Pressekonferenz 2001;(München, 26.01.).
- (27) Eder M, Mehnert W. Pflanzliche Begleitstoffe - wertvolle Hilfstoffe oder überflüssiger Ballast? Pharmazie in unserer Zeit 2000; 29:377-384.
- (28) Möller HJ, Heuberger L. Anxiolytische Potenz von D, L-Kavain. Ergebnisse einer plazebokontrollierten Doppelblindstudie. Münchn med Wschr 1989; 131(37):656-659.
- (29) Lehmann E, Klieser E, Klimke A, Krach H, Spatz R. The efficacy of cavain in patients suffering from anxiety. Pharmacopsychiatry 1989; 22(6):258-262.
- (30) Unger L. Veränderung psychovegetativer Beschwerden unter Therapie mit Kavain. Erfahrungen mit Neuronika® in der Praxis. Therapiewoche 1998; 38:3171-3174.
- (31) Lindenberg D, Pitule-Schödel H. D, L-Kavain im Vergleich zu Oxazepam bei Angstzuständen. Doppelblindstudie zur klinischen Wirksamkeit. Fortschr Med 1990; 108(2):31-34.
- (32) Staedt U, Holm E, Heep J, Rienmüller S, Kortsik C, Steiner G. Zum Wirkungsprofil von D,L-Kavain - Psychometrie, EEG und Fremdbeurteilungsskala. Med Welt 1991; 42:881-891.
- (33) Möller H-J, Ulm K, Glöggler A. Kavain als Hilfe beim Benzodiazepin-Entzug. Münchn med Wschr 1992; 134(37):587-590.
- (34) Pilz E. Anxiolyse mit D,L-Kavain. Eine Alternative zur Neuroleptanxiolyse? TW Neurologie Psychiatrie 1994; 8:325-328.
- (35) Lewin L. Über Piper methysticum (Kawa-Kawa). Berl Klin Wschr 1886;(1):7-10.
- (36) Barsky AJ, Saintfort R, Rogers MP, Borus JF. Nonspecific medication side effects and the nocebo phenomenon. JAMA 2002; 287(5):622-627.
- (37) Reidenberg MM, Lowenthal DT. Adverse nondrug reactions. N Engl J Med 1968; 279:678-679.
- (38) Gauler TC, Weihrauch TR. Placebo. Ein wirksames und ungefährliches Medikament? München: Verlag Urban & Schwarzenberg, 1997.
- (39) Habermann E. Gift und Nocebo - zwei Aspekte der Toxikologie. Med Klinik 1997; 93:113-118.
- (40) Scheler W. Grundlagen der allgemeinen Pharmakologie. Stuttgart: Fischer-Verlag, 1980.
- (41) Hofmann R, Winter U. Therapeutische Möglichkeiten mit Kava Kava bei Angsterkrankungen. Psycho 1996; 22:51-53.
- (42) Stevinson C, Huntley A, Ernst E. A Systematic Review of the Safety of Kava Extract in the

Treatment of Anxiety. Drug safety 2002; 25(4):251-261.

- (43) Chanwai LG. Kava toxicity. Emerg Med 2000; 12:142-145.
- (44) Jappe U, Franke I, Reinhold D, Gollnick HPM. Sebotropic drug reaction resulting from kava-kava extract therapy: a new entity? J Am Acad Dermatol 1998; 38(1):104-106.
- (45) Guro-Razuman S, Anand P, Hu Q, Mir R. Dermatomyositis-like illness following kava-kava ingestion. J Clin Rheumatol 1999; 5(6):342-345.
- (46) Schmidt P, Boehncke WH. Delayed-type hypersensitivity reaction to kava-kava extract. Contact dermatitis 2000; 42:363-364.
- (47) Süß R, Lehmann P. Hämatogenes Kontaktekzem durch pflanzliche Medikamente am Beispiel des Kavawurzelextraktes. Hautarzt 1996; 47:459-461.
- (48) Schelosky L, Raffauf C, Jendroska K, Poewe W. Kava and dopamine antagonism. J Neurol Neurosurg Psychiatry 1995; 58:639-640.
- (49) Jamieson DD, Duffield PH. Positive interaction of ethanol and kava resin in mice. Clin Exp Pharmacol Physiol 1990; 17(7):509-514.
- (50) Herberg K-W. Zum Einfluß von Kava-Spezialextrakt WS 1490 in Kombination mit Ethylalkohol auf sicherheitsrelevante Leistungen. Bericht zu einer doppelblinden, randomisierten, placebokontrollierten Studie. TÜV-Projekt 954-411001 1992;1-24.
- (51) Herberg KW. Fahrtüchtigkeit nach Einnahme von Kava-Spezialextrakt WS 1490. Z Allg Med 1991; 67:842-846.
- (52) Herberg KW. Beeinflusst Kava-Extrakt in Kombination mit Ethylalkohol die Fahrsicherheit? naturamed 1997; 12(7):28-36.
- (53) Loew D, Habs M, Klimm HD, Trunzler G. Angst-, Spannungs- und Unruhezustände. Phytopharmaka für eine rational begründbare vertragsärztliche Verordnung. Piperis methystici rhizoma (Kava-Kava-Wurzelstock). Phytopharmaka-Report. Rationale Therapie mit pflanzlichen Arzneimitteln. Darmstadt: Steinkopff-Verlag, 1999: 78-84.
- (54) Foo H, Lemon J. Acute effects of kava, alone or in combination with alcohol, on subjective measures of impairment and intoxication and on cognitive performance. Drug Alcohol Rev 1997; 16:147-155.
- (55) Mathews JD, Riley MD, Fejo L, Munoz E, Milns NR, Gardner ID et al. Effects of the heavy usage of kava on physical health: summary of a pilot survey in an aboriginal community. Med J Aust 1988; 148(11):548-555.
- (56) Saletu B, Grünberger J, Linzmayer L, Anderer P. EEG-brain mapping, psychometric and psychophysiological studies on central effects of kavain-a kava plant derivative. Human Psychopharmacol 1989; 4:169-190.
- (57) Johnson D, Frauendorf A, Stecker K, Stein U. Neurophysiologisches Wirkprofil und Verträglichkeit von Kava-Extrakt WS 1490: eine Pilotstudie mit randomisierter Auswertung. TW Neurologie Psychiatrie 1991; 5:349-354.
- (58) Münte TF, Heinze HJ, Matzke M, Steitz J. Effects of oxazepam and an extract of kava roots

- (Piper methysticum) on event-related potentials in a word recognition task. *Neuropsychobiology* 1993; 27:46-53.
- (59) Gessner B, Cnota P. Untersuchung der Vigilanz nach Applikation von Kava-Kava-Extrakt, Diazepam oder Placebo. *Z Phytother* 1994; 15(1):30-37.
- (60) Heinze HJ, Münte TF, Steitz J, Matzke M. Pharmacopsychological effects of oxazepam and kava-extract in a visual search paradigm assessed with event-related potentials. *Pharmacopsychiatry* 1994; 27:224-230.
- (61) Herberg KW. Alltagssicherheit unter Kava-Kava-Extrakt, Bromazepam und deren Kombination. *Z Allg Med* 1996; 72:973-977.
- (62) Khanna JM, Chung S, Ho G, Shah G. Acute metabolic interactions of ethanol and drugs. In: Galanter M, editor. *Currents in alcoholism*. New York: Verlag Grune & Stratton, 1980: 93-108.
- (63) Lieber CS. Alcohol and the liver. In: Arias IM, editor. *The liver*. Amsterdam: Excerpta medica, 1982: 92-121.
- (64) Poser W. Arzneitherapie bei Alkoholkranken. In: Dölle WB, Müller-Oerlinghausen B, Schwabe U, editors. *Grundlagen der Arzneitherapie*. Mannheim: Wissenschaftsverlag (Bibliographisches Institut), 1986: 434-437.
- (65) Meyer HJ. *Pharmakologie der Kavadroge*. Habilitationsschrift. Pharmakologisches Institut der Universität Freiburg i.Br., 1966.
- (66) Almeida JC, Grimsley EW. Coma from the health food store: interaction between kava and alprazolam. *Ann Intern Med* 1996; 125:940-941.
- (67) Donadio V, Bonsi P, Zele I, Monari L, Liguori R, Vetrugno R et al. Myoglobinuria after ingestion of extracts of guarana, Ginkgo biloba and kava. *Neurol Sci* 2000; 21:124.
- (68) Norton SA, Ruze P. Kava dermopathy. *J Am Acad Dermatol* 1994; 31(1):89-97.
- (69) Russmann S, Lauterburg BH, Helbling A. Kava hepatotoxicity. *Ann Int Med* 2001; 135(1):68-69.
- (70) Russmann S, Escher M, Stoller R, Lauterburg BH. Hepatotoxicity of Kava Kava (Piper methysticum) containing herbal drugs. Recent cases in Switzerland and investigations regarding the mechanism. *J Exp Klin Pharmakol Toxicol* 2001; 363(4):S40.
- (71) Stoller R. Leberschädigungen unter Kava-Extrakten. *Schweiz Ärzteztg* 2000; 81(24):1335-1336.
- (72) Escher M, Desmeules J. Hepatitis associated with Kava, a herbal remedy for anxiety. *Br Med J* 2001; 322(20.01.01):139.
- (73) Schmidt M, Nahrstedt A. Ist Kava lebertoxisch? Eine Analyse der bekannten Daten zum Leberisiko von Kava-Präparaten. *Dtsch Apoth Ztg* 2002; 142(9):1006-1011.
- (74) Schulze J, Meng G, Siegers C-P. Safety Assessment of Kavalactone-containing Herbal Drugs in Comparison to other Psychotropics. *Wilsede*, 28.06.-30.06.2001: 2001.
- (75) Garcia Rodriguez LA, Wallander MA, Stricker BH. The risk of acute liver injury associated

- with cimetidine and other acid-suppressing anti-ulcer drugs. *Br J Clin Pharmacol* 1997; 43(2):183-188.
- (76) Purcell P, Henry D, Melville G. Diclofenac hepatitis. *Gut* 1991; 32(11):1381-1385.
- (77) Garcia Rodriguez LA, Williams R, Derby LE, Dean AD, Jick H. Acute liver injury associated with nonsteroidal anti-inflammatory drugs and the role of risk factors. *Arch Intern Med* 1994; 154:311-316.
- (78) O'Brian WM. Adverse Reactions to Nonsteroidal Anti-Inflammatory Drugs. *Am J Med* 1986; 80(suppl. 4B):70-80.
- (79) Paulus HE. FDA Arthritis Advisory Committee meeting. *Arthr Rheum* 1982; 25(9):1124-1125.
- (80) Rabinovitz M, Van Thiel DH. Hepatotoxicity of Nonsteroidal Anti-Inflammatory Drugs. *Am J Gastroenterol* 1992; 87(12):1696-1704.
- (81) Orales Diclofenac bald auch ohne Rezeptpflicht? *Ärzte Ztg* 2002; 21(103 (06.06.2002)).
- (82) Bone K. Kava - a safe herbal treatment for anxiety. *Brit J Phytother* 1994; 3:147-153.
- (83) Gebhardt R. Untersuchungen der Hepatotoxizität von Kava-Spissumextrakt an kultivierten Leberzellen. Interner Bericht Harras Pharma Curarina 2001.
- (84) Hsu SY, Lin MH, Lin LC, Chou CJ. Toxicologic studies of dihydro-5,6-dehydrokawain and 5,6-dehydrokawain. *Planta Med* 1994; 60(1):88-90.
- (85) Kretzschmar R. Pharmakologische Untersuchungen zur zentralnervösen Wirkung und zum Wirkungsmechanismus der Kava-Droge (*Piper methysticum* Forst) und Ihrer kristallinen Inhaltsstoffe. In: Loew D, Rietbrock N, editors. *Phytopharmaka in Forschung und klinischer Anwendung*. Darmstadt: Verlag Steinkopff, 1995: 29-38.
- (86) Meyer HJ. Antagonistische Wirkungen genuiner Kavapyrone bei experimentellen Entzündungen und Fieber. *Klin Wschr* 1965; 43:469-470.
- (87) Müller B, Komorek R. Mit Kava behandeln - die Wurzel gegen den Streß. *Wiener med Wschr* 1999; 149(8-10):197-201.
- (88) Sorrentino L. Toxicology Report / Kavapyron Complex (Kavasedon). Dept Exp Pharmacology, University of Neapel , In-House-Report Harras Pharma 1990.
- (89) Malani J. Evaluation of the effects of kava on the liver. <http://www.spc.org.nc/cis/documents/Kava%20article%20DrMalani.pdf> 2002;(March 12, 2002):1-10.
- (90) Spillane PK, Fisher DA, Currie BJ. Neurological manifestations of kava intoxication [letter] [see comments]. *Med J Aust* 1997; 167(3):172-173.
- (91) Spillane PK, Fisher DA, Currie BJ. Neurological manifestations of kava intoxication. *Med J Aust* 1997; 167(3):172-173.
- (92) Schilcher H. Widerruf der Zulassungen von Kava-Kava-Präparaten. Sachverständigenkommission E beim Bundesinstitut für Arzneimittel und Medizinprodukte unterstützt das Veto des ZÄN und bestätigt die Risikoeinschätzung des ZÄN. *Ärztzezschr*

Naturheilverf 2002; 43(8):545.

(93) Experten gegen den Widerruf der Zulassung. Kava-Kava nützt den Patienten. Medical Tribune 2002; 37(28).

(94) Anonym. Kava nur auf Rezept: Das wäre eine Lösung! Ärzte Ztg 2001;(Nr. 213 vom 20.12.):12.

(95) Siegers C-P. BfArM-Schnellschuss. Dtsch Apoth Ztg 2001; 141(48):5729.

(96) Hourmand-Ollivier I, Dargere S, Cohen D, Galais MP, Mosquet B, Rousselot P et al. Hépatite subfulminante mortelle probablement due à l'association bédazépril-hydrochlorothiazide (Briazide). Gastroenterol Clin Biol 2000; 24(4):464.

(97) Weisburst M, Self T, Peace R, Cooper J. Jaundice and rash associated with the use of phenobarbital and hydrochlorothiazide. South Med J 1976; 69(1):126-127.

(98) Abramson M, Littlejohn GO. Hepatic reactions to nifedipine. Med J Aust 1985; 142(1):47-48.

(99) Biour M, Grange JD, Barbare JC, Legendre C, Geri D, Valty J et al. Atteinte hépatique due à la nifedipine. Description d'un cas et revue de la littérature. Therapie 1987; 42(3):301-303.

(100) Davidson AR. Lymphocyte sensitisation in nifedipine-induced hepatitis. Br Med J 1980; 281(6251):1354.

(101) Kiire CF, Rutherford D. Nifedipine-associated jaundice: a second case. East Afr Med J 1986; 63(8):560-561.

(102) Rotmensch HH, Roth A, Liron M, Rubinstein A, Gefel A, Livni E. Lymphocyte sensitisation in nifedipine-induced hepatitis. Br Med J 1980; 281(6246):976-977.

(103) Shaw DR, Misan GM, Johnson RD. Nifedipine hepatitis. Aust N Z J Med 1987; 17(4):447-448.

(104) Welch HG, Lazar B, Gresser J, McMahan BJ. Nifedipine-induced hepatitis. Alaska Med 1986; 28(1):11-12.

(105) Benichou C. Criteria of drug-induced liver disorders. Report of an international consensus meeting. J Hepatol 1990; 11(2):272-276.

(106) Lang I, Huber K, Capek J, Glogar DH, Probst P, Kaindl F. Furosemide and increases in liver enzymes. Ann Intern Med 1988; 109(10):845.

(107) Bellido Casado J, Fernando de Frutos Arribas J, del Rio Fernandez MdC, Mena Martin J. Hepatitis y furosemida. Rev Esp Enferm Dig 1996; 88(11):813-814.

(108) Lagarriga J, Buenrostro C, Rodriguez P, Castaneda J. Hepatonecrosis por furosemida. Lesion privativa de algunas especies? Rev Gastroenterol Mex 1977; 42(3):117-125.

(109) McMurtry RJ, Mitchell JR. Renal and hepatic necrosis after metabolic activation of 2-substituted furans and thiophenes, including furosemide and cephaloridine. Toxicol Appl Pharmacol 1977; 42(2):285-300.

(110) Mitchell JR, Potter WZ, Hinson JA, Jollow DJ. Hepatic necrosis caused by furosemide.

Nature 1974; 251(5475):508-511.

(111) Thorgeirsson SS, Sasame HA, Mitchell JR, Jollow DJ, Potter WZ. Biochemical changes after hepatic injury from toxic doses of acetaminophen or furosemide. *Pharmacology* 1976; 14(3):205-217.

(112) Furosemid - Pankreas og lever. *Tidsskr Nor Laegeforen* 1975; 95(25):1420.

(113) Larrey D, Palazzo L, Benhamou JP. Terfenadine and hepatitis. *Ann Intern Med* 1985; 103(4):634.

(114) Myers MW, Jick H. Terfenadine and risk of acute liver disease. *Br J Clin Pharmacol* 1998; 46(3):251-253.

(115) Sahai A. Terfenadine-induced cholestatic hepatitis. 1996.

(116) Stuckhard P. Vergiftete Leber nach Kava-Kava. *Neue Westfälische* 2002;(153 (July 5)).

(117) Hinzpeter W. Angriff auf die Leber. *Stern* 2002;(23 (May 29)).

(118) Holt C, Csete M, Martin P. Hepatotoxicity of anesthetics and other central nervous system drugs. *Gastroent Clin N Am* 1995; 24(4):853-874.

(119) Hepatitis associated with ranitidine. *JAMA* 1984; 252(23):3253-3254.

(120) Barr GD, Piper DW. Possible ranitidine hepatitis. *Med J Aust* 1981; 2(8):421.

(121) Devuyst O, Lefebvre C, Geubel A, Coche E. Acute cholestatic hepatitis with rash and hypereosinophilia associated with ranitidine treatment. *Acta Clin Belg* 1993; 48(2):109-114.

(122) Cherqui B, Desaint B, Legendre C, Levy VG. Hépatite mortelle chez une patiente traitée par la ranitidine. *Gastroenterol Clin Biol* 1989; 13(11):952-953.

(123) Desaint B, Alperine M, Legendre C, Florent C, Levy VG. Hépatite à la ranitidine. *Gastroenterol Clin Biol* 1985; 9(10):746-747.

(124) Karachalios GN. Ranitidine and hepatitis. *Ann Intern Med* 1985; 103(4):634-635.

(125) Liberopoulos EN, Nonni AB, Tsianos EV, Elisaf MS. Possible ranitidine-induced cholestatic jaundice. *Ann Pharmacother* 2002; 36(1):172.

(126) Proctor JD. Hepatitis associated with ranitidine. *JAMA* 1984; 251(12):1554.

(127) Luparini RL, Rotundo A, Mattace R, Marigliano V. Verosimile epatite autoimmune da ranitidina. *Ann Ital Med Int* 2000; 15(3):214-217.

(128) Ribeiro JM, Lucas M, Baptista A, Victorino RM. Fatal hepatitis associated with ranitidine. *Am J Gastroenterol* 2000; 95(2):559-560.

(129) Souza Lima MA. Hepatitis associated with ranitidine. *Ann Intern Med* 1984; 101(2):207-208.

(130) Souza Lima MA. Ranitidine and hepatic injury. *Ann Intern Med* 1986; 105(1):140.

(131) van Bommel EF, Meyboom RH. Leverbeschadiging door ranitidine. *Ned Tijdschr Geneesk*

1992; 136(9):435-437.

(132) Black M, Scott WE, Jr., Kanter R. Possible ranitidine hepatotoxicity. *Ann Intern Med* 1984; 101(2):208-210.

(133) Hiesse C, Cantarovich M, Santelli C, Francais P, Charpentier B, Fries D et al. Ranitidine hepatotoxicity in renal transplant patient. *Lancet* 1985; 1(8440):1280.

(134) Speeg KV, Jr., Christian DC, Mitchell MC. Ranitidine and acetaminophen hepatotoxicity. *Ann Intern Med* 1984; 100(2):315-316.

(135) Graham DY, Opekun AR, Smith JL, Schwartz JT. Ranitidine and hepatotoxicity. *Ann Intern Med* 1985; 102(3):416.

(136) Hegarty JE. Ranitidine and hepatotoxicity. *Lancet* 1985; 1(8422):223.

(137) Lauritsen K, Havelund T, Rask-Madsen J. Ranitidine and hepatotoxicity. *Lancet* 1984; 2(8417-18):1471.

(138) Lewis JH. Hepatic effects of drugs used in the treatment of peptic ulcer disease. *Am J Gastroenterol* 1987; 82(10):987-1003.

(139) Van Steenberghe W, Vanstapel MJ, Desmet V, Van Kerckvoorde L, De Keyzer R, Brijs R et al. Cimetidine-induced liver injury. Report of three cases. *J Hepatol* 1985; 1(4):359-368.

(140) Hagley MT, Benak RL, Hulisz DT. Suspected cross-reactivity of enalapril- and captopril-induced hepatotoxicity. *Ann Pharmacother* 1992; 26(6):780-781.

(141) Hagley MT, Hulisz DT, Burns CM. Hepatotoxicity associated with angiotensin-converting enzyme inhibitors. *Ann Pharmacother* 1993; 27(2):228-231.

(142) Hartleb M, Biernat U, Kochel A. Drug-induced liver damage - a three-year study of patients from one gastroenterological department. *Med Sci Monit* 2002; 8(4):CR292-CR296.

(143) Jeserich M, Ihling C, Allgaier HP, Berg PA, Heilmann C. Acute liver failure due to enalapril. *Herz* 2000; 25(7):689-693.

(144) Kitai E, Sandiuk A, Zalewski S. Enalapril-induced immunologic impairment of hepatic function. *J Fam Pract* 1991; 33(3):301-302.

(145) Rosellini SR, Costa PL, Gaudio M, Saragoni A, Miglio F. Hepatic injury related to enalapril. *Gastroenterology* 1989; 97(3):810.

(146) Todd P, Levison D, Farthing MJ. Enalapril-related cholestatic jaundice. *J R Soc Med* 1990; 83(4):271-272.

(147) Hürlimann R, Binek J, Oehlschlegel C, Hammer B. Enalapril (Reniten)-assoziierte toxische Hepatitis. *Schweiz Med Wochenschr* 1994; 124(29):1276-1280.

(148) Lunel F, Gripon P, Cadranel JF, Victor N, Opolon P. Hépatite aiguë après la prise de maléate d'énalapril (Rénitec). *Gastroenterol Clin Biol* 1987; 11(2):174-175.

(149) Martin T, Taupignon A, Graf E, Perrin D. Pancréatite et hépatite chez une femme traitée par

maléate d'énalapril. Un cas. *Therapie* 1989; 44(6):449-450.

(150) Mikloweit P, Bienmüller H. Medikamentös induzierte intrahepatische Cholestase durch Flecainidacetat und Enalapril. *Internist (Berl)* 1987; 28(3):193-195.

(151) Droste HT, de Vries RA. Chronic hepatitis caused by lisinopril. *Neth J Med* 1995; 46(2):95-98.

(152) Larrey D, Babany G, Bernuau J, Andrieux J, Degott C, Pessayre D et al. Fulminant hepatitis after lisinopril administration. *Gastroenterology* 1990; 99(6):1832-1833.

(153) Lindgren A, Olsson R. Leverbiverkning vid antihypertensiv terapi. Patientfall av lisinoprolhepatit samt översikt. *Lakartidningen* 1993; 90(16):1557-1558.

(154) Saez-Royuela F, Lopez-Vazquez A, Lopez-Morante A, Diez-Sanchez V, Martin-Lorente JL. Pentoxifylline-induced acute hepatitis. *J Hepatol* 1995; 23(4):482-484.

(155) Brauer R-B, Pfab R, Becker K, Berger H, Stangl M. Fulminantes Leberversagen nach Einnahme des pflanzlichen Heilmittels Kava-Kava. *Z Gastroenterol* 2001; 39:491.

(156) Denie C, Gohy P. Hépatite cytologique attribuable au cisapride. *Gastroenterol Clin Biol* 1992; 16(4):368-369.

(157) Yusoff IF, Nairn P, Morgan CA. Multiple organ failure related to pantoprazole. *Aust N Z J Med* 1999; 29(6):833-834.

(158) Barbare JC, Imbert A, Benkirane A. Du nouveau dans l'hépatotoxicité des médicaments. *Presse Med* 2001; 30(14):673-676.

(159) Fidler H, Dhillon A, Gertner D, Burroughs A. Chronic ecstasy (3,4-methylenedioxymetamphetamine) abuse: a recurrent and unpredictable cause of severe acute hepatitis. *J Hepatol* 1996; 25(4):563-566.

(160) Andreu V, Mas A, Bruguera M, Salmerón JM, Moreno V, Nogué S et al. Ecstasy: a common cause of severe acute hepatotoxicity. *J Hepatol* 1998; 29:394-397.

(161) Saß M, Schnabel S, Kröger J, Liebe S, Schareck WD. Akutes Leberversagen durch Kava-Kava - eine seltene Indikation zur Lebertransplantation. *Z Gastroenterol* 2001; 39:491.

(162) Rotolo V. Itteri in diabetici trattati con sulfaniluree. Su di un caso clinico di ittero da tolazamide. *Friuli Med* 1968; 23(2):257-275.

(163) Babich MM, Pike I, Shiffman ML. Metformin-induced acute hepatitis. *Am J Med* 1998; 104(5):490-492.

(164) Desilets DJ, Shorr AF, Moran KA, Holtzmuller KC. Cholestatic jaundice associated with the use of metformin. *Am J Gastroenterol* 2001; 96(7):2257-2258.

(165) Lin KD, Lin JD, Juang JH. Metformin-induced hemolysis with jaundice. *N Engl J Med* 1998; 339(25):1860-1861.

(166) Barrio J, Castiella A, Cosme A, Lopez P, Fernandez J, Arenas JI. Hepatototoxicidad por cloxacilina. *Rev Esp Enferm Dig* 1997; 89(7):559-560.

- (167) Barrio J, Castiella A, Lobo C, Indart A, Lopez P, Garcia-Bengoechea M et al. Hepatitis colestática aguda secundaria a amoxicilina-acido clavulanico. Papel des acido ursodesoxicoloco en la colestasis inducida por drogas. *Rev Esp Enferm Dig* 1998; 90(7):523-526.
- (168) Bauer TM, Bircher AJ. Drug-induced hepatocellular liver injury due to benzylpenicillin with evidence of lymphocyte sensitization. *J Hepatol* 1997; 26(2):429-432.
- (169) Beeley L, Gourevitch A, Kendall MJ. Jaundice after oral penicillin. *Lancet* 1976; 2(7998):1297.
- (170) Bint AJ. Esters of penicillins--are they hepatotoxic? *J Antimicrob Chemother* 1980; 6(6):697-699.
- (171) Bralet MP, Zafrani ES. Hépatitites dues à l'association amoxicilline-acide clavulanique. Un exemple d'hépatotoxicité biliaire des médicaments. *Ann Pathol* 1996; 16(6):425-429.
- (172) Bustamante BM, Perez AF, Rayon MM, Garcia HA, Berenguer LJ. Hepatitis colestática por amoxicilina-clavulanico. Presentacion de un nuevo caso. *Gastroenterol Hepatol* 1997; 20(4):187-189.
- (173) Caballero Plasencia AM, Valenzuela Barranco M., Martin Ruiz JL, Guilarte Lopez-Manas J. Hepatotoxicidad por amoxicilina, clavulanico o ambos? *Gastroenterol Hepatol* 1997; 20(1):45-46.
- (174) Farrell GC. Drug-induced hepatic injury. *J Gastroenterol Hepatol* 1997; 12(9-10):S242-S250.
- (175) Galindo C, Buenestado J, Rene JM, Pinol MC. Pancreatitis aguda asociada a hepatotoxicidad. *Rev Esp Enferm Dig* 1995; 87(8):597-600.
- (176) George DK, Crawford DH. Antibacterial-induced hepatotoxicity. Incidence, prevention and management. *Drug Saf* 1996; 15(1):79-85.
- (177) Goland S, Malnick SD, Gratz R, Feldberg E, Geltner D, Sthoeger ZM. Severe cholestatic hepatitis following cloxacillin treatment. *Postgrad Med J* 1998; 74(867):59-60.
- (178) Goldstein LI, Ishak KG. Hepatic injury associated with penicillin therapy. *Arch Pathol* 1974; 98(2):114-117.
- (179) Hautekeete ML. Hepatotoxicity of antibiotics. *Acta Gastroenterol Belg* 1995; 58(3-4):290-296.
- (180) Hewitt J, Hammond L. Adverse hepatic events associated with drug therapy. *Med J Aust* 1996; 165(6):347, 350.
- (181) Kurowski V. Cholestatisher Ikterus nach Einnahme von Amoxicillin und Clavulansäure. *Dtsch Med Wochenschr* 1996; 121(12):390-391.
- (182) Mizoguchi Y, Iwasaki M, Tsutsui H, Kobayashi K, Monna T, Morisawa S. Preparation of a drug-induced allergic hepatic disorder model with penicillin as haptén. *Osaka City Med J* 1991; 37(2):133-140.
- (183) Olans RN, Weiner LB. Reversible oxacillin hepatotoxicity. *J Pediatr* 1976; 89(5):835-838.
- (184) Onate J, Montejo M, Aguirrebengoa K, Ruiz-Irastorza G, Gonzalez dZ, Aguirre C. Hepatotoxicity associated with penicillin V therapy. *Clin Infect Dis* 1995; 20(2):474-475.

- (185) Paine TF, Jr. Updating the side effects of the penicillins. *Zhonghua Min Guo Wei Sheng Wu Xue Za Zhi* 1978; 11(3):104-109.
- (186) Perman E. Allvarlig leverbiverkning av penicillin. Ersättning utgick från Läkemedelsförsäkringen. *Lakartidningen* 1998; 95(34):3536.
- (187) Silvain C, Fort E, Levillain P, Labat-Labourdette J, Beauchant M. Granulomatous hepatitis due to combination of amoxicillin and clavulanic acid. *Dig Dis Sci* 1992; 37(1):150-152.
- (188) Westphal JF, Vetter D, Brogard JM. Hepatic side-effects of antibiotics. *J Antimicrob Chemother* 1994; 33(3):387-401.
- (189) Olmos M, Guma C, Colombato LO, Lami G, Miyashiro R, Alvarez E. Lesiones hepáticas por drogas. Presentación de 26 casos. *Acta Gastroenterol Latinoam* 1987; 17(2):105-111.
- (190) Gonzalez-Jimenez D, Varela JM, Calderon E, Galindo J, Gonzalez de la Puente MA. Candesartan and acute liver injury. *Eur J Clin Pharmacol* 2000; 56(9-10):769-770.
- (191) Vallejo I, Garcia Morillo S., Pamies E. Hepatitis aguda por candesartan. *Med Clin (Barc)* 2000; 115(18):719.
- (192) Epeirier JM, Pageaux GP, Coste V, Perrigault PF, Banc P, Larrey D et al. Fulminant hepatitis after carbimazole and propranolol administration. *Eur J Gastroenterol Hepatol* 1996; 8(3):287-288.
- (193) Tarver D, Walt RP, Dunk AA, Jenkins WJ, Sherlock S. Precipitation of hepatic encephalopathy by propranolol in cirrhosis. *Br Med J (Clin Res Ed)* 1983; 287(6392):585.
- (194) Watson P, Hayes JR. Cirrhosis, hepatic encephalopathy, and propranolol. *Br Med J (Clin Res Ed)* 1983; 287(6398):1067.
- (195) Kunze KD, Porst H, Lohmann J, Tschopel L. Lebeschäden durch Dihydralazine und Propranolol. *Zentralbl Allg Pathol* 1985; 130(1):19-29.
- (196) Rene JM, Buenestado J, Sese E, Minana JM. Hepatitis tóxica inducida por valsartán. *Med Clin (Barc)* 2001; 117(16):638.
- (197) Carrillo-Jimenez R, Nurnberger M. Celecoxib-induced acute pancreatitis and hepatitis: a case report. *Arch Intern Med* 2000; 160(4):553-554.
- (198) Galan MV, Gordon SC, Silverman AL. Celecoxib-induced cholestatic hepatitis. *Ann Intern Med* 2001; 134(3):254.
- (199) O'Beirne JP, Cairns SR. Drug Points: Cholestatic hepatitis in association with celecoxib. *BMJ* 2001; 323(7303):23.
- (200) Tanabashi S, Kawase Y, Ukita M, Shiroko J, Kametani M, Kumada H. [A case of chronic hepatitis complicated by subacute thyroiditis during beta-interferon treatment]. *Nippon Shokakibyo Gakkai Zasshi* 1996; 93(7):496-500.
- (201) Yoshida EM, Rasmussen SL, Steinbrecher UP, Erb SR, Scudamore CH, Chung SW et al. Fulminant liver failure during interferon beta treatment of multiple sclerosis. *Neurology* 2001; 56(10):1416.
- (202) Petrogiannopoulos C, Zacharof A. Glibenclamide and liver disease. *Diabetes Care* 1997;

20(7):1215.

- (203) Severe hepatic and cutaneous adverse effects with nevirapine. *Prescrire Int* 2000; 9(48):116.
- (204) Cattelan AM, Erne E, Salatino A, Trevenzoli M, Carretta G, Meneghetti F et al. Severe hepatic failure related to nevirapine treatment. *Clin Infect Dis* 1999; 29(2):455-456.
- (205) Gonzalez de Requena D, Nunez M, Jimenez-Nacher I, Soriano V. Liver toxicity caused by nevirapine. *AIDS* 2002; 16(2):290-291.
- (206) Leitze Z, Nadeem A, Choudhary A, Saul Z, Roberts I, Manthous CA. Nevirapine-induced hepatitis treated with corticosteroids? *AIDS* 1998; 12(9):1115-1117.
- (207) Ormseth EJ, Holtzmuller KC, Goodman ZD, Colonna JO, Batty DS, Sjogren MH. Hepatic decompensation associated with lamivudine: a case report and review of lamivudine-induced hepatotoxicity. *Am J Gastroenterol* 2001; 96(5):1619-1622.
- (208) Palacios R, Santos J, Gonzalez M, Marquez M. Hepatitis y nevirapina. *Med Clin (Barc)* 2000; 114(15):597-598.
- (209) Piliero PJ, Purdy B. Nevirapine-induced hepatitis: a case series and review of the literature. *AIDS Read* 2001; 11(7):379-382.
- (210) Prakash M, Poreddy V, Tiyyagura L, Bonacini M. Jaundice and hepatocellular damage associated with nevirapine therapy. *Am J Gastroenterol* 2001; 96(5):1571-1574.
- (211) Jarousse B, Cohen P, Berlureau P, Bentata M, Mahr A, Guillevin L. Nevirapine induced fulminant hepatitis: Presentation of case and analysis of risk factors. 7th European Conference on Clinical Aspects and Treatment of HIV-Infection, Lisboa, October 23-27 1999.
- (212) Bissell DM, Gores GJ, Laskin DL, Hoofnagle JH. Drug-induced liver injury: mechanisms and test systems. *Hepatology* 2001; 33(4):1009-1013.
- (213) Sabin CA, Fisher M, Churchill D, Pozniak A, Hay P, Easterbrook P et al. Long-term follow-up of antiretroviral-naïve HIV-positive patients treated with nevirapine. *J Acquir Immune Defic Syndr* 2001; 26(5):462-465.
- (214) Pollard RB, Robinson P, Dransfield K. Safety profile of nevirapine, a nonnucleoside reverse transcriptase inhibitor for the treatment of human immunodeficiency virus infection. *Clin Ther* 1998; 20(6):1071-1092.
- (215) Clarke S, Harrington P, Condon C, Kelleher D, Smith OP, Mulcahy F. Late onset hepatitis and prolonged deterioration in hepatic function associated with nevirapine therapy. *Int J STD AIDS* 2000; 11(5):336-337.
- (216) Palmon R, Tirelli R, Braun JF, Kreiswirth S, McMeeking AF, Mullen M et al. Hepatotoxicity associated with non-nucleoside reverse transcriptase inhibitors for the treatment of human immunodeficiency virus and the effect of hepatitis B or C virus infection. *Hepatology* 2000; 32:312A.
- (217) Arranto AJ. Medroxyprogesterone induced changes in rat liver. A light and electron microscopic study. *Pathol Res Pract* 1983; 176(2-4):115-124.
- (218) Rautio A. Liver function and medroxyprogesterone acetate elimination in man. *Biomed*

Pharmacother 1984; 38(4):199-204.

(219) Kremer A, Rios B, Bruno M, Heinrichs G. Utilizacion de medroxiprogesterona en cirrosis hepatica humana. Acta Gastroenterol Latinoam 1985; 15(1):25-31.

(220) Sotaniemi EA, Hynninen T, Ahlqvist J, Ahokas JT, Puoskari U, Pelkonen I. Effects of medroxyprogesterone on the liver function and drug metabolism of patients with primary biliary cirrhosis and chronic active hepatitis. J Med 1978; 9(2):117-128.

(221) Stenback F, Saarni HU, Rautio A, Stengard J, Sotaniemi EA. Reversibility of rat liver cirrhosis by medroxyprogesterone acetate. Toxicol Pathol 1989; 17(1 Pt 1):38-45.

(222) Comparative study of the effects of two once-a-month injectable steroidal contraceptives (Mesigyna and Cyclofem) on glucose metabolism and liver function. United Nations Development Programme/United Population Fund/World Health Organization/World Bank, Special Programme of Research, Development and Research Training in Human Reproduction, Task Force on Long-acting Systemic Agents for Fertility Regulation. Contraception 1998; 57(2):71-81.

(223) Andersson T, Hassan-Alin M, Hasselgren G, Rohss K, Weidolf L. Pharmacokinetic studies with esomeprazole, the (S)-isomer of omeprazole. Clin Pharmacokinet 2001; 40(6):411-426.

(224) Kale-Pradhan PB, Landry HK, Sypula WT. Esomeprazole for Acid peptic disorders. Ann Pharmacother 2002; 36(4):655-663.

(225) Loof L, Adami HO, Gustavsson S, Nyberg A, Nyren O, Lundborg P. Omeprazole: no evidence for frequent hepatic reactions. Lancet 1984; 1(8390):1347-1348.

(226) Navarro JF, Gallego E, Aviles J. Recurrent severe acute hepatitis and omeprazole. Ann Intern Med 1997; 127(12):1135-1136.

(227) Koury SI, Stone CK, La Charite DD. Omeprazole and the development of acute hepatitis. Eur J Emerg Med 1998; 5(4):467-469.

(228) Koury SI, Stone CK, La Charite DD. Acute hepatitis induced by omeprazole. Am J Emerg Med 1998; 16(5):550-551.

(229) Danan G, Trunet P, Bernuau J, Degott C, Babany G, Pessayre D et al. Pirprofen-Induced Fulminant Hepatitis. Gastroenterology 1985; 89:210-213.

(230) Adler E, Benjamin SB, Zimmerman HJ. Cholestatic hepatic injury related to warfarin exposure. Arch Intern Med 1986; 146(9):1837-1839.

(231) Jones DB, Makepeace MC, Smith PM. Jaundice following warfarin therapy. Postgrad Med J 1980; 56(659):671.

(232) Rehnqvist N. Intrahepatic jaundice due to warfarin therapy. Acta Med Scand 1978; 204(4):335-336.

(233) Matsukawa R, Uemura S, Fukuchi S, Tsuruta Y, Murakami S. Thrombosed St. Jude Medical prosthesis with drug induced hepatitis due to warfarin potassium - a case report. Nippon Kyobu Geka Gakkai Zasshi 1994; 42(3):413-415.

(234) Ammon HPT. Arzneimittelneben- und wechselwirkungen. 2 ed. Stuttgart: Wiss. Verlagsges.,

1986.

(235) Romero-Gomez M, Otero MA, Suarez-Garcia E, Garcia DE, Fobelo MJ, Castro-Fernandez M. Acute hepatitis related to omeprazole. *Am J Gastroenterol* 1999; 94(4):1119-1120.

(236) Johnstone D, Berger C, Fleckman P. Acute fulminant hepatitis after treatment with rabeprazole and terbinafine. *Arch Intern Med* 2001; 161(13):1677-1678.

(237) Locatelli M, Colleoni M, Noberasco C, Nole F, Orlando L, Munzone E et al. Hepatic toxicity from cyclophosphamide, methotrexate, fluorouracil (CMF regimen). *Ann Oncol* 1999; 10(11):1394-1395.

(238) Hornowski S, Olkowski L. Przypadek zoltaczki wywołanej 5-fluorouracylem. *Pol Tyg Lek* 1967; 22(40):1536-1537.

(239) Sorensen P, Edal AL, Madsen EL, Fenger C, Poulsen MR, Petersen OF. Reversible hepatic steatosis in patients treated with interferon alfa- 2a and 5-fluorouracil. *Cancer* 1995; 75(10):2592-2596.

(240) Sorensen P, Edal AL, Madsen EL, Fenger C, Poulsen MR, Petersen OF. Reversibel leversteatose hos patienter behandlet med 5-fluoruracil og interferon-alpha. *Ugeskr Laeger* 1997; 159(6):765-767.

(241) Alderman S, Kailas S, Goldfarb S, Singaram C, Malone DG. Cholestatic hepatitis after ingestion of chaparral leaf: confirmation by endoscopic retrograde cholangiopancreatography and liver biopsy. *J Clin Gastroenterol* 1994; 19(3):242-247.

(242) Batchelor WB, Heathcote J, Wanless IR. Chaparral-induced hepatic injury. *Am J Gastroenterol* 1995; 90(5):831-833.

(243) Fleiss PM. Chaparral and liver toxicity. *JAMA* 1995; 274(11):871-872.

(244) Gordon DW, Rosenthal G, Hart J, Sirota R, Baker AL. Chaparral ingestion. The broadening spectrum of liver injury caused by herbal medications. *JAMA* 1995; 273(6):489-490.

(245) Ippen H. Chaparral and liver toxicity. *JAMA* 1995; 274(11):871-872.

(246) Katz M, Saibil F. Herbal hepatitis: subacute hepatic necrosis secondary to chaparral leaf. *J Clin Gastroenterol* 1990; 12(2):203-206.

(247) Smith MD, Gibson GE, Rowland R. Combined hepatotoxicity and neurotoxicity following sulphasalazine administration. *Aust N Z J Med* 1982; 12:76-80.

(248) Stashower ME, Torres RZ. Chaparral and liver toxicity. *JAMA* 1995; 274(11):871-872.

(249) From the Centers for Disease Control and Prevention. Chaparral-induced toxic hepatitis - California and Texas, 1992. *JAMA* 1992; 268(23):3295, 3298.

(250) Chaparral-induced toxic hepatitis - California and Texas, 1992. *MMWR Morb Mortal Wkly Rep* 1992; 41(43):812-814.

(251) Allen ES, Brown WE. Hepatic toxicity of tetracycline in pregnancy. *Am J Obstet Gynecol* 1966; 95(1):12-18.

- (252) Arzneimittelkommission der Deutschen Ärzteschaft. Schwere Nieren- und Leberschäden durch Tetracycline. *Pharmakotherapie* 1965; 2(2):117-118.
- (253) Bjornsson E, Lindberg J, Olsson R. Liver reactions to oral low-dose tetracyclines. *Scand J Gastroenterol* 1997; 32(4):390-395.
- (254) Avanzini F. Epatotossicità delle tetracicline. *Boll Chim Farm* 1965; 104(5):284-289.
- (255) Breen KJ, Schenker S, Heimberg M. Fatty liver induced by tetracycline in the rat. Dose-response relationships and effect of sex. *Gastroenterology* 1975; 69(3):714-723.
- (256) Carson JL, Strom BL, Duff A, Gupta A, Shaw M, Lundin FE et al. Acute liver disease associated with erythromycins, sulfonamides, and tetracyclines. *Ann Intern Med* 1993; 119(7 Pt 1):576-583.
- (257) Combes B, Whalley PJ, Adams RH. Tetracycline and the liver. *Prog Liver Dis* 1972; 4:589-596.
- (258) Damjanov I, Solter D. Ultrastructure of acute tetracycline induced liver change. *Experientia* 1971; 27(10):1204-1205.
- (259) De Jonge HR. Toxicity of tetracyclines in rat-small-intestinal epithelium and liver. *Biochem Pharmacol* 1973; 22(21):2659-2677.
- (260) Lewis M, Schenker S, Combes B. Studies on the pathogenesis of tetracycline-induced fatty liver. *Am J Dig Dis* 1967; 12(5):429-438.
- (261) Ichida F, Watanabe K, Ishiwara S, Inoue K, Tanabe Y. A case of cholestatic jaundice due to tetracycline-triacetyloleandomycin. *Nippon Naika Gakkai Zasshi* 1965; 54(2):142-147.
- (262) Lloyd-Still JD, Grand RJ, Vawter GF. Tetracycline hepatotoxicity in the differential diagnosis of postoperative jaundice. *J Pediatr* 1974; 84(3):366-370.
- (263) Miller SE, MacSween RN, Glen AC, Tribedi K, Moore FM. Experimental studies on the hepatic effects of tetracycline. *Br J Exp Pathol* 1967; 48(1):51-57.
- (264) Peters RL, Edmondson HA, Mikkelsen WP, Tatter D. Tetracycline-induced fatty liver in nonpregnant patients. A report of six cases. *Am J Surg* 1967; 113(5):622-632.
- (265) Porokhniak LA, Drogovoz SM, Rogozhin BA. [Action of hepatoprotective agents in a tetracycline lesion of the liver]. *Antibiot Med Biotekhnol* 1987; 32(4):282-285.
- (266) Robinson MJ, Rywlin AM. Tetracycline-associated fatty liver in the male. Report of an autopsied case. *Am J Dig Dis* 1970; 15(9):857-862.
- (267) Skakun NP, Oleinik AN. [Tetracycline lesions of the liver and their treatment (a review of the literature)]. *Vrach Delo* 1984;(11):91-95.
- (268) Skakun NP, Stepanova NI. [Effectiveness of legalon and essentielle in a tetracycline-induced liver lesion]. *Antibiot Med Biotekhnol* 1986; 31(10):781-784.
- (269) Stewart DJ. A polychromatic specimen. The result of jaundice and tetracycline. *Dent Pract Dent Rec* 1967; 17(9):313-314.

- (270) Zussman WV. Hepatic alterations following experimental tetracycline toxicity in rats. *Anat Rec* 1968; 162(3):301-311.
- (271) Vysotsky IB. [Seasonal efficacy of antioxidants in tetracycline lesions of the liver]. *Antibiotiki* 1984; 29(8):590-594.
- (272) Cai Q, Benson MA, Talbot TJ, Devadas G, Swanson HJ, Olson JL et al. Acute hepatitis due to fluoxetine therapy. *Mayo Clin Proc* 1999; 74(7):692-694.
- (273) Capella D, Bruguera M, Figueras A, Laporte J. Fluoxetine-induced hepatitis: why is postmarketing surveillance needed? *Eur J Clin Pharmacol* 1999; 55(7):545-546.
- (274) Castiella A, Arenas JI. Fluoxetine hepatotoxicity. *Am J Gastroenterol* 1994; 89(3):458-459.
- (275) Johnston DE, Wheeler DE. Chronic hepatitis related to use of fluoxetine. *Am J Gastroenterol* 1997; 92(7):1225-1226.
- (276) Shuster J. Fluoxetine and hepatitis. *Nursing* 2000; 30(12):78.
- (277) Mars F, Dumas de la Roque G, Goissen P. Hépatite aigue lors du traitement par la fluoxetine. *Gastroenterol Clin Biol* 1991; 15(3):270-271.
- (278) Bobichon R, Bernard G, Mion F. Atteinte hépatique aigue lors d'un traitement par la fluoxetine. *Gastroenterol Clin Biol* 1993; 17(5):406-407.
- (279) Cooper GL. The safety of fluoxetine - an update. *Br J Psychiatry Suppl* 1988; 153(Suppl. 3):77-86.
- (280) Friedenberg FK, Rothstein KD. Hepatitis secondary to fluoxetine treatment. *Am J Psychiatry* 1996; 153(4):580.
- (281) Bendele RA, Adams ER, Hoffman WP, Gries CL, Morton DM. Carcinogenicity studies of fluoxetine hydrochloride in rats and mice. *Cancer Res* 1992; 52(24):6931-6935.
- (282) Cadranel JF, Di M, V, Cazier A, Pras V, Bachmeyer C, Olympio P et al. Atrium and paroxetine-related severe hepatitis. *J Clin Gastroenterol* 1999; 28(1):52-55.
- (283) de Man RA. Ernstige hepatitis toegeschreven aan paroxetine (Seroxat). *Ned Tijdschr Geneesk* 1997; 141(11):540-542.
- (284) Odeh M, Misseleveh I, Boss JH, Oliven A. Severe hepatotoxicity with jaundice associated with paroxetine. *Am J Gastroenterol* 2001; 96(8):2494-2496.
- (285) Hautekeete ML, Colle I, van Vlierberghe H, Elewaut A. Symptomatic liver injury probably related to sertraline. *Gastroenterol Clin Biol* 1998; 22(3):364-365.
- (286) Bellaiche G, Lamouri N, Slama JL, Ley G, Paugam B. [Cytolytic hepatic lesion associated with the ingestion of pirtanide]. *Gastroenterol Clin Biol* 1995; 19(4):444-445.
- (287) Yamamoto M. [Toxic hepatitis induced by vitamin A]. *Nippon Rinsho* 1985; 43(6):1187-1191.
- (288) Coxon DT, Curtis RF, Howard B. Ipomeamarone, a toxic furanoterpenoid in sweet potatoes

- (Ipomea batatas) in the United Kingdom. *Food Cosmet Toxicol* 1975; 13(1):87-90.
- (289) Tolman KG. Drugs and the liver. *Med J Aust* 1977; 2(20):655-656.
- (290) Najarian JS. Hepatic necrosis. *N J Med* 1996; 93(1):15.
- (291) Schiano TD, Bellary SV, Cassidy MJ, Thomas RM, Black M. Subfulminant liver failure and severe hepatotoxicity caused by loratadine use. *Ann Intern Med* 1996; 125(9):738-740.
- (292) Abbruzzese A, Swanson J. Jaundice after therapy with chlordiazepoxid hydrochloride. *N Engl J Med* 1965; 273(6):321-322.
- (293) Hall RCW. The benzodiazepines. *AFP* 1978; 17(5):131-134.
- (294) Horwitz D. Adverse reactions to diazepam (Letter to the Editor). *JAVMA* 1994; 205(7):966.
- (295) Cacioppo J, Merlis S. Chlordiazepoxid hydrochloride (Librium) and jaundice: report of a case. *Am J Psychiatry* 1961; 117:1040-1041.
- (296) Hollister LE, Motzenbecker FP, Degan RO. Withdrawal reactions from chlordiazepoxide (Librium). *Psychopharmacologica* 1961; 2:63-68.
- (297) Cunningham ML. Acute hepatic necrosis following treatment with amitriptyline and diazepam. *Br J Psychiatry* 1965; 111(480):1107-1109.
- (298) Cook G, Sherlock S. Jaundice and its relation to therapeutic agents. *Lancet* 1965; 1:175-179.
- (299) Winkelmayr R. Subicterus following the administration of thioridazine and chlordiazepoxide. *Delaware Med J* 1966;334-336.
- (300) Kratzsch KH, Buttner W, Reinhardt G. Intrahepatische Cholestase nach Chlordiazepoxid - Beitrag zur Differentialdiagnose des Arzneimittelikterus. *Z Gesamte Inn Med* 1972; 27(9):408-411.
- (301) Pickering D. Hepatic necrosis after chlordiazepoxide therapy. *N Engl J Med* 1966; 274(25):1449.
- (302) Lo K-J, Eastwood IR, Eidelman S. Cholestatic jaundice associated with chlordiazepoxide (Librium) therapy. *Am J Dig Dis* 1967; 12(8):845-849.
- (303) Fors B, Nilsson F. Hepatit sannolikt indicerad av diazepam-medicinering. *Lakartidningen* 1968; 65(46):4528-4531.
- (304) Franks E, Jacobs WH. Cholestatic jaundice possibly due to benzodiazepine-type drugs. *Mo Med* 1975; 72:605-606.
- (305) Klatskin G. Toxic and drug-induced hepatitis. In: Schiff L, editor. *Diseases of the liver*. Philadelphia: J.B. Lippincott Co., 1975: 604-710.
- (306) Stacher G. Intrahepatische Cholestase nach einer hochdosierten Kombinationstherapie mit Diazepam und Barbituraten bei Tetanus-Patienten. *Wien Klin Wochenschr* 1973; 85(22):401-406.
- (307) Davison K, Farquharson RG, Khan MC, Majid A. A double blind comparison of alprazolam, diazepam and placebo in the treatment of anxious out-patients. *Psychopharmacology (Berl)* 1983;

80(4):308-310.

(308) Rosanelli K. Über die Wirkung von pränatal verabreichtem Diazepam auf das Frühgeborene. *Geburtsh Frauenheilk* 1970; 36:713-724.

(309) McIntosh A. Hyperbilirubinaemia in neonates. *Med J Aust* 1970; 2:101-102.

(310) Fang MH, Ginsberg AL, Dobbins WO. Cholestatic jaundice associated with flurazepam hydrochloride. *Ann Int Med* 1978; 89(3):363-364.

(311) Reynolds R, Lloyd DA, Slinger RP. Cholestatic jaundice induced by flurazepam hydrochloride. *Can Med Assoc J* 1981; 124:893-894.

(312) Parker JL. Potassium clorazepate (Tranxene)-induced jaundice. *Postgrad Med J* 1979; 55:908-910.

(313) Roy-Byrne P, Vittone BJ, Uhde TW. Alprazolam-related hepatotoxicity. *Lancet* 1983;786-787.

(314) Bacher NM, Lewis HA, Field PB. Combined alprazolam and neuroleptic drug in treating schizophrenia. *Am J Psychiatry* 1986; 143(10):1311-1313.

(315) Judd FK, Norman TR, Marriott PF, Burrows GD. A case of alprazolam-related hepatitis. *Am J Psychiatry* 1986; 143(3):388-389.

(316) Cobden I, Record CO, White RWB. Fatal intrahepatic cholestasis associated with triazolam. *Postgrad Med J* 1981; 57:730-731.

(317) Noyes R, Jr., DuPont RL, Jr., Pecknold JC, Rifkin A, Rubin RT, Swinson RP et al. Alprazolam in panic disorder and agoraphobia: results from a multicenter trial. II. Patient acceptance, side effects, and safety. *Arch Gen Psychiatry* 1988; 45(5):423-428.

(318) Weber E. *Taschenbuch der unerwünschten Arzneimittelwirkungen*. 2 ed. Stuttgart, New York: Gustav Fischer Verlag, 1988.

(319) Tedesco FJ, Mills LR. Diazepam (Valium) hepatitis. *Dig Dis Sci* 1982; 27(5):470-472.

(320) Owen G, Smith THF, Agersborg HPKJr. Toxicity of some benzodiazepine compounds with CNS activity. *Tox Appl Pharmacol* 1970; 16:556-570.

(321) Kvetina J, Guitani PA, Pugliatti C, Veneroni E. Effect of diazepam on liver function of rats. *Pharmacol* 1969; 2:17-20.

(322) Center SA, Elston TH, Rowland PH, Rosen DK, Reitz BL, Brunt JE et al. Fulminant hepatic failure associated with oral administration of diazepam in 11 cats. *JAMA* 1996; 209(3):618-625.

(323) Levy JK. Adverse reactions to diazepam (Letter to the Editor). *JAVMA* 1994; 205(7):966.

(324) Chatterjee S, Chatterjee J, Chaudhuri K, Basu S, Maiti C. Hepatotoxicity of diazepam. Structural and trace metal studies in rat. *Biol Trace Element Res* 1997; 57:239-250.

(325) Mach G, Gladysz A. Nawracająca żółtaczka w przebiegu naturalnych i jatrogennych zaburzeń estrogenowych. *Pol Tyg Lek* 1979; 34(49):1923-1924.

- (326) Adlercreutz H, Ikonen E. Oral contraceptives and liver damage. *Br Med J* 1964; 2:1133.
- (327) Baines GF. Jaundice in a patient taking norethisterone compound tablets. *Lancet* 1965; 1:108-109.
- (328) Coe JE, Ishak KG, Ross MJ. Estrogen-induced hepatic toxicity and hepatic cancer: differences between two closely related hamster species. *Liver* 1998; 18(5):343-351.
- (329) Carnasciali E, Pezzini F. Ittero da estro-progestinici. Descrizione di un caso. *Minerva Med* 1977; 68(32):2249-2251.
- (330) Cullberg C, Lundström R, Stenram U. Jaundice during treatment with oral contraceptive Lyndiol. *Br Med J* 1965; 1:695-697.
- (331) Eisalo A, Järvinen PA, Luukainen T. Hepatic impairment during the intake of contraceptive pills; clinical trial with post-menopausal women. *Br Med J* 1964; 2:426-427.
- (332) Elliott AJ, Hendry J. Cholestatic jaundice complicating pregnancy: recurrence after norethynodrel with ethinylestradiol (Enovid). *Canad Med Assoc J* 1965; 92:344-345.
- (333) Fawcett JW, Pedersen DL. Oral contraceptives and liver damage. *Br Med J* 1964; 2:755.
- (334) Larsson-Cohn U, Stenram U. Jaundice during treatment with oral contraceptive agents: report of two cases. *JAMA* 1965; 193(6):422-426.
- (335) Larsson-Cohn U. Oral contraception and liver-function tests. *Br Med J* 1965; 1:1414-1415.
- (336) Palva IP, Mustala OO. Oral contraceptives and liver damage. *Br Med J* 1964; 2:688.
- (337) Perez-Mera R, Shields C. Jaundice associated with norethindrone acetate therapy. *N Engl J Med* 1962; 267(22):1137-1138.
- (338) Smetana H. Histopathology of drug-induced liver disease. *Ann NY Acad Sci* 1963; 104:821-846.
- (339) Sotaniemi E, Kreuz KE, Scheinin TM. Oral contraceptives and liver damage. *Br Med J* 1964; 2:1264-1265.
- (340) Stoll B, Andrews JT, Motteram R, Upfill J. Oral contraceptives and liver damage. *Br Med J* 1965; 1:723.
- (341) Tyler ET. Oral contraceptives and liver damage. *Br Med J* 1964; 2:843.
- (342) Foss GL, Simpson SL. Oral methyltestosterone and jaundice. *Br Med J* 1959; 1:259-263.
- (343) Dunning MF. Jaundice associated with norethandrolone (Nilevar) administration. *JAMA* 1958; 167:1242-1243.
- (344) Koszalka MF. Medical obstructive jaundice: report of death due to methyltestosterone. *Lancet* 1957; 77:51-54.
- (345) Schaffner F, Popper H, Chesrow E. Cholestasis produced by administration of norethandrolone. *Am J Med* 1959; 26:249-254.

- (346) Peters JH, Randall AHJr, Mendeloff J, Peace R, Coberly JC, Hurley MB. Jaundice during administration of methylestrenolone. *J Clin Endocrinol* 1958; 18:114-115.
- (347) Schaffner F, Popper H, Perez V. Changes in bile canaliculi produced by norethandrolone: electron microscopic study of human and rat liver. *J Lab Clin Med* 1960; 56:623-628.
- (348) Shaw RK, Gold GL. Jaundice associated with norethandrolone (Nilevar) therapy. *Ann Int Med* 1960; 52:428-434.
- (349) Seelen JC. Complications during administration of methylestrenolone. *J Clin Endocrinol* 1958; 18:1137-1138.
- (350) Darnis F, Poupon R. Complications hépato-biliaires de l'oestrogénothérapie. *Rev Prat* 1979; 29(21):1783-1789.
- (351) Jochem V, Kirkpatrick R, Greenson J, Brogan M, Sturgis T, Cook-Glenn C. Fulminant hepatic failure related to omeprazole. *Am J Gastroenterol* 1992; 87(4):523-525.
- (352) del Rio Fernandez M, Plagaro Cordero ME, de Frutos Arribas JF, Bellido Casado J, Velicia Llanes R. Encefalopatía hepática relacionada con omeprazol. *Rev Esp Enferm Dig* 1997; 89(7):574-575.
- (353) Arnold R, Koop H. Omeprazole: long-term safety. *Digestion* 1989; 44 Suppl 1:77-86.
- (354) Aithal GP, Day CP, Leathart JB, Daly AK. Relationship of polymorphism in CYP2C9 to genetic susceptibility to diclofenac-induced hepatitis. *Pharmacogenetics* 2000; 10(6):511-518.
- (355) Babany G, Pessayre D, Benhamou JP. Hépatite au diclofénac. *Gastroenterol Clin Biol* 1983; 7(3):316.
- (356) Babany G, Bernuau J, Danan G, Rueff B, Benhamou JP. Hépatite fulminante chez une femme prenant de la glafénine et du diclofénac. *Gastroenterol Clin Biol* 1985; 9(2):185.
- (357) Bhogaraju A, Nazeer S, Al Baghdadi Y, Rahman M, Wrestler F, Patel N. Diclofenac-associated hepatitis. *South Med J* 1999; 92(7):711-713.
- (358) Breen EG, McNicholl J, Cosgrove E, McCabe J, Stevens FM. Fatal hepatitis associated with diclofenac. *Gut* 1986; 27(11):1390-1393.
- (359) Ciccolunghi SN, Chaudri HA, Schubiger BI, Reddrop R. Report on a long-term tolerability study of up to two years with diclofenac sodium (Voltaren). *Scand J Rheumatol Suppl* 1978;(22):86-96.
- (360) Deshayes P, Leloet X, Bercoff E, Fouin-Fortunet H. Hépatite au diclofénac: une observation. *Presse Med* 1984; 13(30):1847.
- (361) Dierkes-Globisch A, Schafer R, Mohr HH. Asymptomatische Diclofenac-induzierte akute Hepatitis. *Dtsch Med Wochenschr* 2000; 125(25-26):797-800.
- (362) Dunk AA, Walt RP, Jenkins WJ, Sherlock SS. Diclofenac hepatitis. *Br Med J (Clin Res Ed)* 1982; 284(6329):1605-1606.
- (363) Greaves RR, Agarwal A, Patch D, Davies SE, Sherman D, Reynolds N et al. Inadvertent diclofenac rechallenge from generic and non-generic prescribing, leading to liver transplantation for

fulminant liver failure. *Eur J Gastroenterol Hepatol* 2001; 13(1):71-73.

(364) Hackstein H, Mohl W, Puschel W, Stallmach A, Zeitz M. Diclofenac-assozierte akute cholestatische Hepatitis. *Z Gastroenterol* 1998; 36(5):385-389.

(365) Helfgott SM, Sandberg-Cook J, Zakim D, Nestler J. Diclofenac-associated hepatotoxicity. *JAMA* 1990; 264(20):2660-2662.

(366) Iveson TJ, Ryley NG, Kelly PM, Trowell JM, McGee JO, Chapman RW. Diclofenac associated hepatitis. *J Hepatol* 1990; 10(1):85-89.

(367) Jick H, Derby LE, Garcia Rodriguez LA, Jick SS, Dean AD. Liver disease associated with diclofenac, naproxen, and piroxicam. *Pharmacotherapy* 1992; 12(3):207-212.

(368) Jones AL, Latham T, Shallcross TM, Simpson KJ. Fulminant hepatic failure due to diclofenac treated successfully by orthotopic liver transplantation. *Transplant Proc* 1998; 30(1):192-194.

(369) Lascar G, Gripon P, Levy VG. Hépatite aigue mortelle au cours d'un traitement par le diclofénac (Voltarène). *Gastroenterol Clin Biol* 1984; 8(11):881-882.

(370) Mazeika PK, Ford MJ. Chronic active hepatitis associated with diclofenac sodium therapy. *Br J Clin Pract* 1989; 43(3):125-126.

(371) Nos P, Palau J, Perez-Aguilar F, Berenguer J. Hepatitis asociada a la toma de Diclofenac. *Rev Esp Enferm Dig* 1992; 81(5):367.

(372) Ouellette GS, Slitzky BE, Gates JA, Lagarde S, West AB. Reversible hepatitis associated with diclofenac. *J Clin Gastroenterol* 1991; 13(2):205-210.

(373) Paret Masana A., Guarga Rojas A., Urrutia de Diego, Sabria Leal M. Hepatitis aguda y Diclofenac sódico. *Rev Clin Esp* 1986; 179(9):476.

(374) Ramakrishna B, Viswanath N. Diclofenac-induced hepatitis: case report and literature review. *Liver* 1994; 14(2):83-84.

(375) Sallie R. Diclofenac hepatitis. *J Hepatol* 1990; 11(2):281.

(376) Sallie RW, McKenzie T, Reed WD, Quinlan MF, Shilkin KB. Diclofenac hepatitis. *Aust N Z J Med* 1991; 21(2):251-255.

(377) Schapira D, Bassan L, Nahir AM, Scharf Y. Diclofenac-induced hepatotoxicity. *Postgrad Med J* 1986; 62:63-65.

(378) Scully LJ, Clarke D, Barr RJ. Diclofenac induced hepatitis. 3 cases with features of autoimmune chronic active hepatitis. *Dig Dis Sci* 1993; 38(4):744-751.

(379) Selz F, Cereda JM. Hépatite subfulminante mortelle au diclofénac. *Rev Med Suisse Romande* 1993; 113(12):985-987.

(380) Snijder RJ, Dinant HJ, Stricker BH. Dodelijke leverbeschadiging tijdens gebruik van diclofenac. *Ned Tijdschr Geneesk* 1987; 131(46):2088-2090.

(381) Vila Santasuana A, Cid Panella R, Roure Nuez C, Martinez Montauti J, Ortega Enciso YL.

Hepatitis aguda por diclofenaco. *Gastroenterol Hepatol* 1997; 20(3):164-165.

(382) Hovette P, Touze JE, Debonne JM, Delmarre B, Rogier C, Schmoor P et al. Hépatite cholestatique et insuffisance rénale aigue au cours d'un traitement par diclofénaç. *Ann Gastroenterol Hepatol (Paris)* 1989; 25(6):257-258.

(383) Catalano ME. Worldwide safety experience with diclofenac. *Am J Med* 1986; 80(suppl. 4B):81-87.

(384) Jackowitz AI, Walker BK. Agranulocytosis and hepatitis as a result of Mexican drug therapy. *Drug Intell Clin Pharm* 1984; 18(1):66-68.

(385) Besnard M, Debray D, Durand P, Cezard JP, Navarro J. Sulfasalazine-induced fulminant hepatitis in pediatric Crohn's disease: report of two cases. *J Pediatr Gastroenterol Nutr* 1998; 26(1):119-120.

(386) Besnard M, Debray D, Durand P, Fabre M, Chardot C, Cezard JP. Hépatite fulminante chez deux enfants traités par la salazopyrine pour une maladie de Crohn. *Arch Pediatr* 1999; 6(6):643-646.

(387) Boyer DL, Li UK, Fyda JN, Friedman RA. Case Report. Sulfasazine-induced hepatotoxicity in children with inflammatory bowel disease. *J Pediatr Gastroenterol Nutr* 1989; 8:528-532.

(388) Caspi D, Fuchs D, Yaron M. Sulphasalazine induced hepatitis in juvenile rheumatoid arthritis. *Ann Rheum Dis* 1992; 51:275-276.

(389) Chester AC, Diamond LH, Schreiner GE. Hypersensitivity to salicylazosulfapyridine. *Arch Intern Med* 1978; 138:1138-1139.

(390) Curley RK, Macfarlane AW. Fatal multisystemic toxicity associated with prophylaxis with pyrimethamine and sulfadoxine. *Br Med J* 1985; 290:471-472.

(391) Dujovne CA, Chan CH, Zimmerman HJ. Sulfonamide hepatic injury. Review of the literature and report of a case due to sulfamethoxazole. *N Engl J Med* 1967; 277(15):785-788.

(392) Farr M, Symmon DPM, Bacon PA. Case Report. Raised serum alkaline phosphatase and aspartate transaminase levels in two rheumatoid patients treated with sulphasalazine. *Ann Rheum Dis* 1985; 44:798-800.

(393) Fich A, Schwartz J, Braverman D, Zifroni A, Rachmilewitz D. Sulphasalazine hepatotoxicity. *Am J Gastroenterol* 1984; 79(5):401-402.

(394) Gremse DA, Bancroft J, Moyer MS. Case Report. Sulfasalazine hypersensitivity with hepatotoxicity, thrombocytopenia, and erythroid hyperplasia. *J Pediatr Gastroenterol Nutr* 1989; 9:261-263.

(395) Gulley RM, Mirza A, Kelly CE. Hepatotoxicity of salicylazosulfapyridine. *Am J Gastroenterol* 1979; 72:561-564.

(396) Gyssens IC, de Bock RF, Peetermans ME. Sulfasalazine-allergie: koorts, huidrash, hepatitis en T-lymfocytose. *Ned Tijdschr Geneesk* 1989; 133(32):1608-1610.

(397) Haines JD. Hepatotoxicity after treatment with sulfasalazine. *Postgrad Med J* 1986; 79(5):193-198.

- (398) Jennings PE, Blandford RL, Rosenthal FD. Acute sulphasalazine hepatotoxicity. *Postgrad Med J* 1986; 62:305-306.
- (399) Kanner RS, Tedesco FJ, Kalser MH. Azulfidine- (sulfasalazine-) induced hepatic injury. *Am J Dig Dis* 1978; 23(10):956-958.
- (400) Larcan A, Lambert H, Janot C, Perarnaud J, Delorme N, Tonnel F. Hépatite mortelle au cours d'un traitement par sulfasalazine. *Therapie* 1982; 37(3):315-319.
- (401) Leroux JL, Ghezail M, Chertok P, Blotman F. Hypersensitivity reaction to sulfasalazine: skin rash, fever, hepatitis and activated lymphocytes. *Clin Exp Rheumatol* 1992; 10(4):427.
- (402) Losek JD, Werlin SL. Sulfasalazine hepatotoxicity. *Am J Dis Child* 1981; 135:1070-1071.
- (403) Marinos G, Riley J, Painter DM, McCaughan GW. Sulfasalazine-induced fulminant hepatic failure. *J Clin Gastroenterol* 1992; 14(2):132-135.
- (404) Mihas AA, Goldenberg DJ, Slaughter RL. Sulfasalazine toxic reactions. Hepatitis, fever, and skin rash with hypocomplementemia and immune complexes. *JAMA* 1978; 239(24):2590-2591.
- (405) Namias A, Bhalotra R, Donowitz M. Reversible sulfasalazine-induced granulomatous hepatitis. *J Clin Gastroenterol* 1981; 3(2):193-198.
- (406) Pears JS, Morley KD. Fatal hypersensitivity reaction to sulphasalazine. *Br J Rheumatol* 1989; 28(3):274-275.
- (407) Poland GA, Love KR. Marked atypical lymphocytosis, hepatitis, and skin rash in sulfasalazine drug allergy. *Am J Med* 1986; 81(4):707-708.
- (408) Pullar T, Hunter JA, Capell HA. Sulphasalazine and hepatic transaminases. *Ann Rheum Dis* 1987; 46:421.
- (409) Ribe J, Benkov KJ, Thung SN, Shen SC, LeLeiko NS. Fatal massive hepatic necrosis: a probable hypersensitivity reaction to sulfasalazine. *Am J Gastroenterol* 1986; 81(3):205-208.
- (410) Rubin R. Sulfasalazine-induced fulminant hepatic failure and necrotizing pancreatitis. *Am J Gastroenterol* 1994; 89(5):789-791.
- (411) Sotolongo RP, Neefe LI, Rudzki C, Ishak K. Hypersensitivity reaction to sulfasalazine with severe hepatotoxicity. *Gastroenterology* 1978; 75(1):95-99.
- (412) Miller JDB, Broom J. Sulphasalazine hepatotoxicity after 15 years' successful treatment for ulcerative colitis. *Br Med J* 1983; 287:96.
- (413) Wheelan KR, Cooper B, Stone MJ. Multiple hematologic abnormalities associated with sulfasalazine. *Ann Int Med* 1982; 97(5):726-727.